

Description of envenomation by the “gusano-pollo” caterpillar (*Megalopyge opercularis*) in Venezuela.

*Luisana Avilán*¹, *Belsy Guerrero*², *Edinoovsky Álvarez*³ and *Alexis Rodríguez-Acosta*⁴.

¹Centro de Ingeniería Genética (CIGEN), Laboratorio de Fisiología Animal, Universidad de los Andes, Mérida, Venezuela, ²Laboratorio de Fisiopatología, Centro de Medicina Experimental, Instituto Venezolano de Investigaciones Científicas, Caracas, Venezuela,

³Clínica Albarregas, Mérida, Venezuela y ⁴Sección de Ultraestructura Toxinológica, Instituto Anatómico, Universidad Central de Venezuela, Caracas, Venezuela.

Key words: Caterpillar, Lepidoptera, *Megalopyge opercularis*, neurotoxins, venom.

Abstract. Lepidoptera is a large order of insects, with more than 180,000 species world-wide, showing larval stages of butterflies and moths known as wormlike caterpillars. Almost 12 families of butterflies around the world are capable of causing severe human injuries, varying from dermatitis, renal failure, hemostatic alterations, respiratory failure and neurotoxic symptoms. These caterpillars are coated in long, hair-like setae containing venom to protect themselves against aggressive predators. The setae cause a painful reaction, upon contact, due to presence of neurotoxins. These caterpillars are extensively dispersed all through North America and often, during the dry and wet seasons in tropical regions, being able to sustain two annual larval generations. There exist several species of *Megalopyge* caterpillars; however, *Megalopyge opercularis* is the most widely distributed species in Latin America and the United States. This work reports, to our knowledge, the first case of envenomation by the “gusano-pollo” (*Megalopyge opercularis*), a stinging caterpillar, described in Venezuela. The patient in this report presented severe symptoms, including systemic reactions such as intense hand pain irradiated to the upper arm, restricted swelling, headache, dizziness, serious chest distress and shock-like symptoms that required hospitalization. Symptoms improved upon treatment with opiate analgesic drugs.

Descripción del envenenamiento causado por la oruga “gusano-pollo” (*Megalopyge opercularis*) en Venezuela.

Invest Clin 2010; 51(1): 127 - 132

Palabras clave: Oruga, Lepidoptera, *Megalopyge opercularis*, neurotoxina, veneno

Resumen. Lepidoptera es un orden de insectos con más de 180,000 especies descritas en el ámbito mundial, con estadios larvales de mariposas conocidas como orugas parecidas a gusanos. Cerca de 12 familias de mariposas alrededor del mundo son capaces de causar lesiones graves que van desde una dermatitis hasta la insuficiencia renal, incluyendo alteraciones de la hemostasia, fallo respiratorio y síntomas neurotóxicos. Estas orugas están cubiertas de largas cerdas, parecidas a pelos, que contienen veneno y lo usan para protegerse contra sus predadores. La cerda causa una reacción dolorosa, debido a la presencia de neurotoxinas. Estas orugas se encuentran ampliamente esparcidas en Norteamérica y a menudo durante las estaciones seca y lluviosa, en regiones tropicales, pudiendo crear 2 generaciones de larvas al año. Existen varias especies de estas orugas, sin embargo, *Megalopyge opercularis* es la especie más extensamente distribuida en América Latina y los Estados Unidos. Este trabajo refiere, a nuestra revisión de la literatura, el primer caso descrito de envenenamiento por el “Gusano-pollo” (*Megalopyge opercularis*) en Venezuela. El caso en estudio presentó síntomas muy severos, incluyendo las reacciones sistémicas, así como dolor intenso en la mano, irradiado a la parte alta del miembro, edema restringido, cefalea, mareos, opresión retroesternal y síntomas parecidos al choque, que requirieron su hospitalización. La sintomatología mejoró con opiáceos y analgésicos fuertes.

Received: 03-04-2009. Accepted: 11-02-2010.

INTRODUCTION

Among a group known as slug caterpillars, there are small larval moths also known in Venezuela as “gusano-pollo” (*Megalopyge opercularis*), which belong to the Megalopygida family. Until now, this caterpillar has not been described from a medical standpoint in Venezuela. The current work reports a new pathological entity in our Country. The caterpillar is able to cause stings in all larvae stages and lesions are proportional to the size of the insect and the susceptibility of each victim. This caterpillar (gusano-pollo) is oval-shaped, and roofed in feathery hairs that decrease

into dorsal breakaway spines (1). Upon contact with their spines, they discharge toxins containing highly neurotoxic activity. These caterpillars are found living in colonies on many trees, including lemon, eucalyptus, acacia, pine and ornamental trees, from where they fall onto the victims producing multiple stings (1).

In this case study, a patient presented an envenomation triggered for the spines of the caterpillar, which produced severe pain, burning, swelling, chest distress, and a headache. To the best of our knowledge, this is the first case study in Venezuela caused by this caterpillar, and this work sheds light on the symptoms with the pur-

pose of aiding in the diagnoses of the clinical case by caused by the venom of this caterpillar.

CASE REPORT

Case description

We discuss the case of a 48-year-old female gardener from Mérida city (Mérida state, Venezuela) (Fig. 1) who complained of immediate pain when a “hairy brunette caterpillar” (*Megalopyge opercularis*) fell across her fingers (left hand). This caterpillar is one of more than 50 species of caterpillars that can cause envenomation in the western hemisphere and we consider it to be one of the most dangerous.

The patient described that the burning itch due to the tiny spines was instantaneous and felt like that of a wasp sting, followed by an increasing burning sensation that slowly irradiated toward the hand. In approximately two hours, the pain had irradiated to the whole arm (with the same level of intensity) and then to the chest, but no paralytic symptoms were observed. A sharp, contraction-like pain persisted through out the night, only slightly diminishing upon the administration of opiaceous analgesic drugs. The following

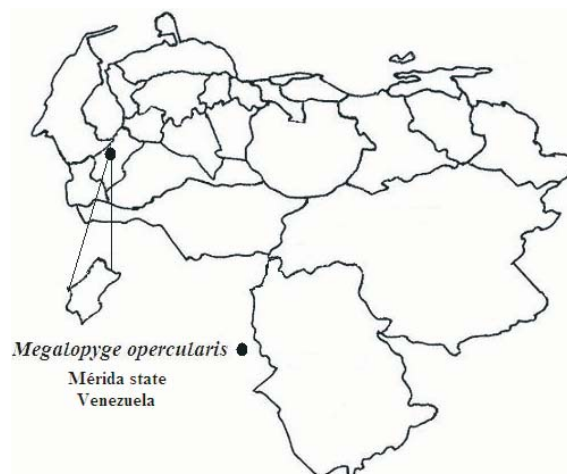


Fig. 1. Geographical location of the caterpillar “gusano-pollo” (*Megalopyge opercularis*) reported in Venezuela.

morning, the pain in the finger had decreased, but persisted in the chest, disappearing later in the evening.

One minute after the patient was stung, small, shiny, light, reddish-brown papules of approximately 1 mm in diameter, emerged above the exterior of the inflamed spot. As the local symptoms disappeared, two small red punctures surrounded by a light erythema persisted for about 3 days. There was a trace of hemorrhage around the punctured area giving it a petechial aspect (Fig. 2).




Fig. 2. Lesion in middle finger, left hand caused by *Megalopyge opercularis* sting.

Laboratory results

The blood work revealed alterations in the white blood cells count: 12,200 (mm^3) (normal control: 5,000 – 10,000/ mm^3), lymphocytes $13.2 \times 10^9/\text{L}$ (normal control: $1.0\text{-}4.8 \times 10^9/\text{L}$). The platelet count showed a moderate reduction to 148,000 (mm^3) (normal controls: 200,000 to 300,000/ mm^3).

Granulocytes: $1.83 \times 10^9/\text{L}$ (normal control: $1.8\text{-}8 \times 10^9/\text{L}$); hemoglobin: 14 g/L (normal control: 12-16 g/L) and creatine 1.2 mg/dL (normal control: 0.8 to 1.2 mg/dL) showed normal results.

Early results obtained within 24 h after caterpillar exposure indicated moderate coagulation abnormalities. On clinic arrival, prothrombin time (PT): 14.0 s (control: 12.4 s); partial thromboplastin time (PTT): 32.0 s (control 27.7 s); fibrinogen (Fg): 280 mg/dL (normal range is 200-400 mg/dL). After 12 h, PT: 13.41 s (control 12.4 s); PTT: 31.7 s (control: 27.7 s); Fg: 275 mg/dL.

Caterpillar description

Megalopyge opercularis matures in envelopes attached to brushwood. They are teardrop-like with elongated silky hairs. The color of the larvae varies from grimy white to golden-brown to dark charcoal gray, and often with a streak of bright orange running longitudinally. The mature larva (caterpillar) is 2.5-3.5 cm in length, with eight pairs of suction-cup like claspers on the back of the body (prolegs) (Figs. 3A and 3B). The adult moth has rounded wings covered with long undulating hair ranging from light orange to lemon yellow, with hairy legs and fuzzy black feet. The mid-body contains hairs that are small spines that release venom upon contact. The head and prolegs are not detectable from the top. The adult moth having a life-span of one week lays eggs on shrubs and trees and within a few days the larva




Fig. 3. Caterpillar (*Megalopyge opercularis*). A. Dorsal view. B. Ventral view.

come out feeding mainly on deciduous trees and shrubs (2).

DISCUSSION

The caterpillar *Megalopyge opercularis* has developed exceptional practices of defense against predators with biological interactions including defensive mimicry and proteolytic, neurotoxic and allergenic toxins. The venomous molecules can accumulate in the spines, tegument and urticating hairs, and they are formed by glandular epithelial cells located under the larvae's skin, which are spread by the hemolymph (2, 3). Caterpillars owning merely venomous spines are described as phanerotoxic; while

caterpillars containing toxins in the hemolymph and not in the spines are known as cryptotoxic (4). Caterpillar envenomation always demands consultation, hospitalization and even treatment in an emergency unit care. It is essential to recognize the offending venomous caterpillar species in order to determine the risks. In a study carried out by Everson *et al.* (1990) (5), the clinical effects frequently reported were local pain, erythema and swelling in 96, 89 and 72% of affected patients, respectively. Uncommon responses, including muscle spasms, paresthesia and radiating pain to an extremity, such as those observed in our current case, were noted in 26% of patients. Symptoms, such as nausea, serious chest distress and intense irradiating pain, frequently confuse the clinical diagnosis by the physicians, since health care workers are unacquainted that this symptomatology is usually caused by the venom of this caterpillar. In addition, knowledge of these toxic animals is scarce among people and even worse amid physicians. Further studies will be necessary to describe the biochemical and toxic activities of their venom in order to evaluate the need of antivenom.

In the last century, considerable occurrences of puss caterpillar (*M. opercularis*) stings in school age children from San Antonio and Galveston (Texas, USA) were described (5, 6). Characteristic sting sites incorporated uncovered arms, faces, heads and particularly the necks behind the shirt collar (5). Very little is known about the venom of *M. opercularis*, but there is a very similar caterpillar in the USA known as the buss caterpillar (*Lagoa crispate*), which has a protein in its venom with high kallikrein activity. The high tannin content in the diet of *L. crispate* is reflected in spine extracts, found to be high in tannins (7). These extracts contain toxic activity, but is lost with time. Lamdin *et al.* (7) isolated fractions from the extract of *L.*

crispate by gel filtration and found them to be void of hyaluronidase, protease and phosphohydrolase activities.

In terms of coagulation screening, prothrombin time (PT) and partial thromboplastin time (PTT) were slightly subtly prolonged, and the levels of fibrinogen (Fg) were not affected. However, it is known that these tests on many occasions are only altered 48 h after the accident (8), and this patient was not given a follow up screening. The patient did present a subtle leukocytosis with a high lymphocytosis. As it is known, transient absolute lymphocytosis is an under recognized phenomenon that has been depicted in patients with emergency medical circumstances, including trauma (9).

From a therapeutic point of view, the treatment for *M. opercularis* envenoming has been inconsistent, and many patients turn to domestic therapy with some level of achievement. For instance, some apply adhesive tape to the affected area to remove the spines deposited by the caterpillars. Furthermore, ice, baking soda, steroid cream, antihistamine or oat (*Avena sativa*) derived lotions, have been commonly used. Eagleman (2) reported that for severe pain, codeine, meperidine HCl, or morphine would sometimes be administered, since salicylates were not helpful. However, injury to the eyes should be attended by an ophthalmologist without delay. The use of systemic corticosteroids has also been suggested to alleviate the symptoms caused by these caterpillars (10, 11).

As mentioned above, very little is known about the activities of the venom obtained from this caterpillar, and a study is currently under way to define *in vitro* hemostatic activities along with *in vivo* lethal doses. Thus far, preliminary activity on fibrin plates is promising (data not shown), and further studies that will involve a battery of assays should reveal information

that can be compared to the clinical aspects of envenoming.

ACKNOWLEDGEMENTS

This work was developed under the FONACIT grant No. PG 2005000400.

REFERENCES

1. **Diaz JH.** The evolving global epidemiology, syndromic classification, management, and prevention of caterpillar envenoming. *Am J Trop Med Hyg* 2005; 72:347-357.
2. **Eagleman DM.** Envenomation by the asp caterpillar (*Megalopyge opercularis*). *Clin Toxicol (Phila)* 2008; 46:201-205.
3. **Gilmer PM.** A comparative study of the poison apparatus of certain lepidopterous larvae. *Ann Entomol Soc Am* 1925; 18: 203-239.
4. **Mebs D.** Butterflies, moths, and their caterpillars. Mebs D, ed. *Venomous and Poisonous Animals: A Handbook for Biologists, Toxicologists, and Toxinologists, Physicians and Pharmacists*. Boca Raton, FL: CRC Press; 2002, p 205-208.
5. **Everson GW, Chapin JB, Normann SA.** Caterpillar envenomations: a prospective study of 112 cases. *Vet Hum Toxicol* 1990; 32:114-119.
6. **Micks DW.** Clinical effects of the "puss caterpillar" (*Megalopyge opercularis*) on man. *Tex Rep Biol Med* 1952; 10:399-405.
7. **Lamdin JM, Howell DE, Kocan KM, Murphey DR, Arnold DC, Fenton AW, Odell GV, Ownby CL.** The venomous hair structure, venom and life cycle of *Logoa crispata*, a puss caterpillar of Oklahoma. *Toxicon* 2000; 38:1163-1189.
8. **Arocha-Piñango CL, Layrisse M.** Fibrinolysis produced by contact with a caterpillar. *Lancet*. 1969; 1(7599):810-812.
9. **Teggatz JR, Parkin J, Peterson L.** Transient atypical lymphocytosis in patients with emergency medical conditions. *Arch Pathol Lab Med* 1987; 111:712-714.
10. **Rosen T.** Caterpillar dermatitis. *Dermatologic Clinics*. 1990; 8:245-252.
11. **Erickson T, Ahrens WR, Aks S, Baum C, Ling L.** *Pediatric toxicology: Diagnosis and management of the poisoned child*. New York: McGraw-Hill Professional; 2004, p. 501.