
Autism associated to a deficiency of complexes III and IV of the mitochondrial respiratory chain.

José Guevara-Campos¹, Lucía González-Guevara², Paz Briones³, Ester López-Gallardo⁴, Nuria Bulán³, Eduardo Ruiz-Pesini⁴, Denisse Rammarine¹ y Julio Montoya⁴.

¹“Felipe Guevara Rojas” Hospital, Pediatrics Service. University of Oriente, El Tigre-Anzoátegui, ²Epilepsy and Encephalography Unit, El Tigre-Anzoátegui, Venezuela, ³Institut de Bioquímica Clínica, Sección de Errores Congénitos del Metabolismo, Servicio de Bioquímica y Genética Molecular, Hospital Clínic, CIBERER and CSIC, Barcelona, Spain, ⁴Biochemistry and Molecular and Cell Biology, University of Zaragoza. CIBERER. Zaragoza, Spain.

Key words: autism, muscular biopsy, mitochondrial disease, lactate, pyruvate.

Abstract. Autism is the prototype of generalized developmental disorders or what today are called autism spectrum disorders. In most cases it is impossible to detect a specific etiology. It is estimated that a causative diagnosis may be shown in approximately 10-37% of the cases, including, congenital rubella, tuberous sclerosis, chromosome abnormalities such as fragile X syndrome and 22q13.3 deletion syndrome, Angelman, Williams, Smith-Magenis, Sotos, Cornelia de Lange, Möbius, Joubert and Goldenhar syndromes, Ito's hypomelanosis, as well as certain cerebral malformations and several inherited metabolic disorders. The case of a 3-year old girl is described, who was considered as autistic according to the criteria established by the DSM-IV manual for psychiatric disorders. She showed a delay in psychomotor development since she was 18 months old; she pronounces very few words (10), points to some objects, does not look up and it is hard to establish eye contact with her. She has paradoxical deafness and therefore, does not respond when called or when she is given orders, she is beginning to walk. She has not convulsions. Laboratory tests showed an anion gap of 31.6 mEq/L, lactate: 2.55: mmol/L, pyruvate: 0.06 mmol/L, and elevated lactate to/pyruvate ratio: 42.5. Under optical microscopy a muscular biopsy showed a reduction of the diameter of muscular fibers. The study of energy metabolism showed a partial deficiency of complexes III and IV of the respiratory chain, which allowed us to conclude that this was a mitochondrial dysfunction with an autistic clinical spectrum.

Autismo asociado a una deficiencia del Complejo III y IV de la cadena respiratoria mitocondrial.

Invest Clin 2010; 51(3): 423 - 431

Palabras clave: autismo, biopsia muscular, enfermedad mitocondrial, lactato, piruvato.

Resumen. El autismo es el prototipo de los trastornos generalizados del desarrollo o de lo que hoy se denominan trastornos del espectro autista. En la mayoría de los casos no es posible detectar una etiología específica. Se estima que aproximadamente entre el 10 y el 37% de los casos se puede demostrar una causa específica, como la rubéola congénita, la esclerosis tuberosa, anomalías cromosómicas como el síndrome del cromosoma X frágil y la microdelección 22q13.3, los síndromes de Angelman, Williams, Smith-Magenis, Sotos, Cornelia de Lange, Möebius, Joubert y Goldenhar, la hipomelanosis de Ito, así como algunas malformaciones cerebrales y varios trastornos metabólicos. Se describe un preescolar de 3 años de edad, de sexo femenino, catalogada como autista de acuerdo a los criterios establecidos por el manual DSM-IV para trastornos psiquiátricos. Presentaba un retraso en la adquisición de su desarrollo psicomotor desde los 18 meses, pronunciaba pocas palabras (10), señalaba algunos objetos, no utilizaba la mirada y era difícil establecer contacto ocular con ella, mostraba sordera paradójica, por lo que no respondía cuando se le llamaba ni cuando se le daban órdenes. Empezaba a caminar y no había presentado convulsiones. Los exámenes de laboratorio mostraban anión gap: 31,6 mEq/L, lactato: 2,55 mmol/L, piruvato: 0,06 mmol/L y una relación lactato/piruvato elevada de: 42,50 mmol/L. La biopsia muscular practicada reportó en la microscopía óptica disminución del diámetro de las fibras musculares y el estudio del metabolismo energético demostró una deficiencia parcial en los complejos III y IV de la cadena respiratoria, el cual nos permitió concluir que se trataba de una disfunción mitocondrial con espectro autista.

Received: 17-05-2009. Accepted: 08-04-2010.

INTRODUCTION

Autism was described by Leo Kanner, a psychiatrist (1) in 1943, as a biological disorder whose essential alteration consists of an innate disturbance of affective contact.

The physiopathology of this disorder has not yet been well defined (2). The most relevant current hypotheses, which need to be confirmed, establish that the cause of autism is a genetic alteration, with polygenic probability (3).

Recent studies have linked autism to a defective production of mitochondrial energy, associated to biochemical endophenotypes (4) that may be involved in the etiology of this multifactor disorder, causing brain function alteration when compared to normal development. In addition, there is broad evidence that mitochondrial DNA (mtDNA) mutations may cause neurological and metabolic disease in children and adults that produce recognized phenotypes and whose characteristics are transmitted

as features of polygenic complexes (5), such as in autism. There are consistently repeated reports that Parkinson's and Alzheimer's diseases are associated to defects of complexes I and IV, respectively, of the mitochondrial respiratory chain (6, 7). Incidence is four times more frequent in males than in females (8).

The criteria used to diagnose autism are described in the diagnostic and statistical manual of the American Psychiatric Association –DSM-IV (9)– that it has a high degree of specificity and sensibility in certain age groups and among individuals with different language and cognitive skills.

Classical mitochondrial diseases are commonly associated with abnormalities in laboratory tests that include: high lactate, pyruvate and ammonium and low carnitine levels. These markers are useful to evaluate mitochondrial diseases. These laboratory tests parameters have also been described in some autistic individuals without any other evidence of classical mitochondrial disease (10).

A previous study showed that approximately 35% of autistic children presenting high blood lactate, had classical mitochondrial disease (11) and treatment with nutritional supplements (coenzyme Q, vitamin C, thiamine, pyridoxine, L-carnitine) was capable of reducing the symptoms only in autistic individuals with mitochondrial dysfunction (11, 12).

Classical mitochondrial diseases affect a small number of autistic individuals and typically, these diseases occur because of genetic abnormalities and defects in the respiratory chain.

In this report we show a child presenting autism with characteristics of a mitochondrial disease that presents a partial deficiency of complexes III and IV of the respiratory chain.

CLINICAL CASE

A 3-year old girl was diagnosed as autistic according to the criterion established in the DSM-IV Manual of the American Psychiatric Association. With regard to psychomotor development, she started to sit up when she was 2 years old, to crawl at 25 months old and to wander around on her own when she was 3 years old. When she was 24 months old she used words such as “dad” and “mom” in a referential manner, but she would not make three-word phrases. When she was 18 months old, her deficient social interaction, with a serious disruption of her communicative and affective capacity, drew the family's attention. Developmental stagnation was detected, including a certain regression of her expressive language, with limited gestural ability and seriously compromised comprehension capacity.

She was the term product of a third pregnancy resulting from a non-consanguineous relationship. The delivery was normal. Her A_gar scores were 7 at 1 minute, and 9 at 5 and 10 minutes. Birth weight: 2,600 g (10th percentile), height: 53 cm (50th percentile) and immunization was according to her age. There was not family history of epilepsy, migraine or neurological disease. Personal background: hospitalized two times due to an urinary infection.

On physical examination weight: was 16 kg (50th percentile), height: 95 cm (50th percentile), head circumference: 51 cm (50th percentile), with regular general condition. No dysmorphic features or cutaneous blemishes were observed. Respiratory and cardiovascular systems were normal. A reduction of muscular tone was noted. Deep tendon reflexes in the upper and lower limbs were normal. Discrete motor discoordination, ataxic walk, absence of

stereotypy, Deep tendon reflexes were normal. No alteration of the cranial pairs, and she did not utter words, only guttural sounds.

Laboratory tests showed the following results: hemoglobin: 12.2 g/dL; hematocrit: 39%; leucocytes: 9,000/mm³, 65% neutrophils, 35% lymphocytes and 5% eosinophiles; platelets 251,000/mm³; glucose: 70 mg/dL; urea 23 mg/dL; creatinine 0.6 mg/dL; alkaline phosphatase 40 IU/L; calcium 9 mg/dL, AST 34 U/L, ALT 20 U/L, prothrombin time 13 sec, thromboplastin time 32 sec, lactate dehydrogenase 420 U/L, VDRL negative, HIV negative, Toxo-test negative, T3: 1.95 MU/mL, T4 1.53 MU/mL, amino acids normal, organics acids in urine normal, qualitative biotinidase present, anion gap 31.6 mEq/L, lactate 2.55 mmol/L, pyruvate 0.06 mmol/L, lactate pyruvate ratio 42.5 mM, ammonium normal (11 Umol/L), karyotype normal.

The determination of serum electrolytes was: sodium 137, mEq/L; potassium: 4.75 mEq/L; chlorine: 102 mEq/L; uric acid 6.2 mg/dL; phosphorus 5 mg/dL. The blood gases revealed: pH 7.22, PCO₂:27 mmHg, PO₂: 95 mmHg, HCO₃: 15,5 mEq/L, EB: -6,5 mEq/L. kidney ultrasonography and micturating cystogram were normal. The auditory evoked potentials were normal.

The electromyography and conduction velocity of the peroneal and tibial nerves were normal. Brain magnetic resonance showed disruption of the myelinization of the white matter.

Positron Emission Tomography (PET) of the brain showed glucose hypometabolism in the regions of the thalamus (Fig. 1).

Interictal electroencephalograms (EEG) performed awake and in natural sleep revealed intermittent spike and wave activity

of 1 and 2 Hz in the left central temporal region.

The echocardiogram showed the presence of a slight defect in the mitral valve.

Due to the lactic acidosis, with an increase in the lactate / pyruvate ratio, a biopsy of the femoral muscle was performed with optic microscopy that showed: skeletal muscle with diffused reduced diameter fibers (unspecific myopathic alterations) and electron microscopy showed lipid droplets in the muscle fibers, without organelle changes.

The determination of the mitochondrial respiratory chain in the muscle homogenate showed a partial deficiency of complex III and a slightly diminished complex IV (Table I).

Molecular genetics studies were performed by isolation of total DNA from blood and muscle by standard procedures, analysis of the 3243 mutation and subsequent sequencing of the whole mitochondrial genome from the muscle sample. The primers and conditions for the whole mtDNA sequencing are available upon request. The results of the sequencing showed a series of reported polymorphisms that defined her as an individual belonging to the T haplogroup and candidate mutation m.11930A>G that produce an amino acid change Ile395Val in the mitochondrial gene coding for the complex I ND4 subunit, that has not been reported before. The m 11930 A>G transition was not found in more than 3,500 patients and controls from all around the world. This mutation is present in homoplasmy in the patient's and her mother's DNA. The study of mtDNA depletion by real time PCR analysis was negative.

Treatment of patient was started with L-carnitine: 1 g twice a day, riboflavin 50 mg per day, thiamine 50 mg per day, Coenzyme Q 30 mg three times a day, and phenobarbital 50 mg once a day.

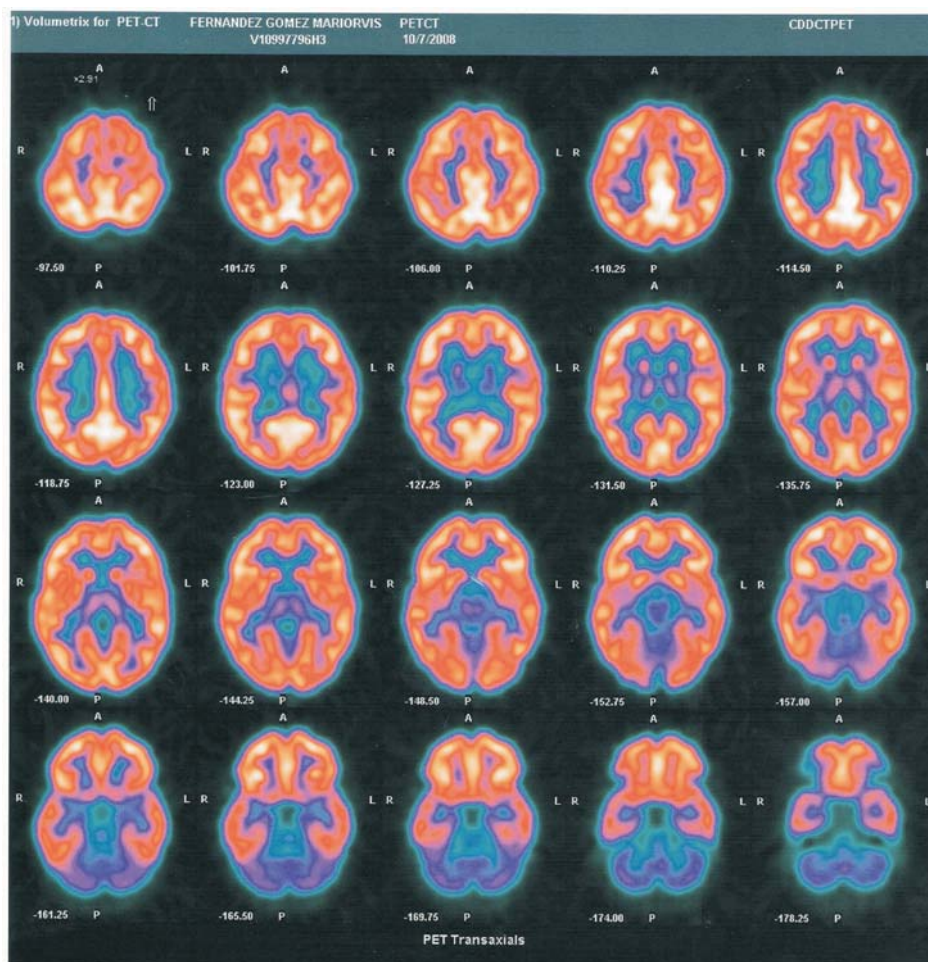


Fig. 1. PET of the brain showed glucose hypometabolism in the regions of thalamus.

TABLE I
ENERGY METABOLIC STUDY IN MUSCLE BIOPSY

Enzymatic activity	Results	Units	Reference ranges
Citrate Synthase (CS)	152	nmol/min mg pr	71-200
NADH: Cit C oxidoreductase (Complex I+III)	79	mU/U CS	107-560
Succinate: Cit C oxidoreductase (Complex II+III)	46	mU/U CS	75-149
Succinate: DCPIP oxidoreductase (Complex II)	33	mU/U CS	33-69
DDH (+PMS)	79	mU/U CS	57-239
Decylubiquinol: cyt c oxidoreductase (Complex III)	355	mU/U CS	610-1760
Cytochrome C oxidase (Complex IV)	520	mU/U CS	590-1300

Results are compatible with a partial Complex III deficiency. In addition, cytochrome c oxidase (COX, Complex IV) activity is slightly reduced.

The patient is currently receiving speech therapy, and she is attending a special education school. The behavior and speech disorders described above are still present. The family gave informed consent for the publication of the case.

DISCUSSION

Classical mitochondrial diseases are caused by genetic abnormalities or flaws in the mitochondrial respiratory pathway, and may be accompanied by autism in some individuals. However, in many cases of autism there is evidence of mitochondrial dysfunction without the classical features associated to mitochondrial disease (13).

Mitochondrial dysfunction seems to be common in autistic patients and it appears with mild signs and symptoms. In previous studies (10) carried out with 120 autistic patients, it has been shown that 24% of the cases presented atypical or syndromic autism. In 5 of the 11 patients to whom mitochondrial function studies were performed, a defined metabolic defect was found with alteration of complexes I, IV and/or V of the mitochondrial respiratory chain. These authors suggest that mitochondrial etiology was one of the most commonly involved in syndromic autism, although it is probably under-diagnosed (14).

In our case, the patient presented a delay in motor development: at 18 months old the inability for verbal communication and incapacity for affective and social interaction were obvious.

The existence of epileptic encephalopathy was investigated, although she did not have clinical convulsion crises. West Syndrome was also ruled out since she did not have infantile spasms (15, 16). Glucose hypometabolism in the temporal lobes of children with West syndrome that evolved into autism has been reported (17) but, in our case, the PET performed showed hypo-

metabolism in the thalamus region (18, 19).

Furthermore, no activity compatible with the Landau-Kleffner syndrome was found in the encephalogram, as has been described in patients with autistic features (20, 21), nor any spike and wave in the temporal regions, or the existence of an electric status during sleep. The prevalence of epilepsy and EEG alterations in autism is clearly more prevalent than in the normal population. Any type of convulsion may occur in autistic children. The abnormalities found on the EEG are either focal or multifocal, and this activity increases during sleep and has been detected in a large percentage of children with autism, with or without the presence of convulsions (22).

Mitochondrial etiology must be considered in those patients that suffer an autistic regression manifestation associated with epileptiform activity on the electroencephalogram or with epilepsy during the second year of life (23).

Although organic aminoacidopathy and acidurias were ruled out, the elevation of the anion gap of lactate and pyruvate, with an elevated lactate-pyruvate ratio > 20 mEq/L, pointed out to mitochondrial disease (24). The study of the activity of the respiratory chain complexes showed the existence of a partial deficiency of Complex III and a slight reduction of the cytochrome C oxidase (complex IV).

The most important difference between idiopathic autism and a metabolic disease with progressive deterioration consists that, in the former case only the skills involved in autism are affected: communication and social interaction; while in a metabolic disease the regression is much broader (epilepsy, motor impairment, and multi-systemic impairment), as in the case at hand.

The acronym "HEADD syndrome" can be applied to patients with syndromic au-

tism that have associated hypotonia (H), epilepsy (E), autism (A) and psychomotor developmental delay (DD), related to mitochondrial pathology. Our patient completely fulfils the criterion described for this syndrome. The muscular biopsy showed, in seven of the eight patients with HEADD syndrome, abnormalities in the respiratory chain complexes in the subunits codified for mitochondrial DNA. mtDNA mutations were identified in five of the cases, but these did not correspond to the classical mutations associated with mitochondrial encephalomyopathies, such as MELAS, MERRF and Kears-Sayre or Leigh syndromes. The acronym HEADD is presented to facilitate the following of mitochondrial defects in patients with this clinical constellation, after other causes have been excluded (25).

Lactic acidosis has been associated to a variety of clinical conditions and it may be due to gene mutations at the nuclear or mitochondrial level (26). Many genetic disorders have been reported that are associated to lactic acidosis, such as a deficiency of the pyruvate dehydrogenase complex and of the enzymatic complexes of the respiratory chain (27).

Although these enzymatic defects of the respiratory chain are often associated to myopathies caused by mitochondrial DNA or nuclear DNA (nDNA) abnormalities (28), many point mutations in the mitochondrial tRNA genes have been well documented in disorders such as diabetes mellitus, migraine, neurodegenerative diseases and autism (29), producing recognized phenotypes of diseases that are otherwise transmitted as a polygenic complex, such as autism (4).

Sequencing of mtDNA showed a number of population polymorphisms and a mutation within the ND4 gene (m.11930A>G) that has not been reported before in patients and control populations. However,

this mutation is homoplasmic state in both parents (asymptomatic) and daughter. The conservative aminoacid change (Ile for Val) is not important enough to cause a disease. Beside this, there was not a complex I deficiency.

Other studies did not show any of those mtDNA mutations in 120 children with autism, despite hyperlactacidemia in 14 of them and that definitive respiratory chain dysfunction in five patients was described (10).

As to treatment, mitochondrial function disorders do not have a specific therapy. Many drugs have been used to improve mitochondrial function and final energy production. Primary disorders of the mitochondrial respiratory chain may be associated to disorders within the autistic range and therefore, this diagnostic possibility must be considered in any child with characteristics that are compatible with that disease.

In general, the prognosis of autism is variable and it probably depends on the severity of the underlying etiologies (30).

As a conclusion, there is a relationship between autism and mitochondrial dysfunction. Despite all the biochemical, histochemical and genetic limitations, including the molecular study, that condition the final diagnosis of mitochondrial diseases in childhood, in order to reach an early diagnosis and treatment, we must consider this etiological possibility for primary disorders of the mitochondrial chain in children that show general and specific developmental disorders.

ACKNOWLEDGMENTS

This study was supported by Institution of Health Carlos III-FIS (P107-0045, P108-0307, and P108-90253) from the Spanish Ministry of Health and Diputation General of Aragón (B33 and P1083-2008).

The CIBER of Rare Diseases (CIBERER) is an initiative of the ISCIII, Spain.

REFERENCES

1. **Kanner L.** Autistic disturbances of affective contact. *Nervous Child* 1943; 2:217-250.
2. **Volkmar FR, Pauls D.** Autism. *Lancet* 2003; 362:1133-1141.
3. **Martos-Pérez J.** Autismo, neurodesarrollo y detección temprana. *Rev Neurol* 2006; 42 (supl 2):S99-S101.
4. **Jay J, Imtiaz F.** Mitochondrial energy-deficient endophenotype in autism. *Am J Biochem Biotech* 2008; 4(2):198-207.
5. **Ruiz-Pesini E, Lott MT, Procaccio V, Poole JC, Brandon MC, Mishmar D, Yi C, Kreuziger J, Baldi P, Wallace DC.** An enhanced MITOMAP with a global mtDNA mutational phylogeny. *Nucleic Acids Res* 2007; 35:823-828.
6. **Brown MD, Shoffner JM, Kim YL, Jun AS, Graham BH, Cabell MF, Gurley DS, Wallace DC.** Mitochondrial DNA sequence analysis of four Alzheimer's and Parkinson's disease patients. *Am J Med Genet* 1996; 61(3):283-289.
7. **Parker WD Jr, Parks JK, Swerdlow RH.** Complex I deficiency in Parkinson's disease frontal cortex. *Brain Res* 2008; 1189: 215-218.
8. **Kaufmann WE, Capone GT, Clarke M, Hohmann CF.** Autism in genetic intellectual disability. In Zimmerman AW, ed. *Autism: Current theories and evidences*. Totowa, N.J.: Humana Press 2008. p. 81-108.
9. **American Psychiatric Association.** Pervasive developmental disorders. *Diagnostic and Statistical Manual of Mental Disorders*. 4 ed. Washington, DC; American Psychiatric Association 1994:65-98.
10. **Oliveira G, Diogo L, Grazina M, Garcia P, Ataíde A, Marques C, Miguel T, Borges L, Vicente AM, Oliveira CR.** Mitochondrial dysfunction in autism spectrum disorders: a population-based study. *Dev Med Neurol* 2005; 47:185-189.
11. **Rossignol DA, Bradstreet JJ.** Evidence of mitochondrial dysfunction in autism and implications for treatment. *A J Biochem Biotechnol* 2008; 4(2):208-217.
12. **DiMauro S, Mancuso M.** Mitochondrial diseases: therapeutic approaches. *Biosci Rep* 2007; 27(1-3):125-137.
13. **Serajee FJ, Zhang H, Huq AHMM.** Prevalence of common mitochondrial point mutations in autism. *Neuropediatrics* 2006; 37(suppl1):S127.
14. **García-Peñas JJ.** Autismo, epilepsia y patología del lóbulo temporal. *Rev Neurol* 2009; 48:35-45.
15. **Guevara-Campos J, González-Guevara L.** Treatment of infantile spasm: a Venezuelan experience. *J Pediatr Neurol* 2005; 3:159-163.
16. **Guevara-Campos J, González-Guevara L, Urbáez J.** Espasmos infantiles y síndrome de West: Una Revisión. *Arch Venez Puer Ped* 2004; 67:187-193.
17. **Chugani HT, da Silva E, Chugani DC.** Infantile spasm: III Prognostic implications of bitemporal hypometabolism on positron emission tomography. *Ann Neurol* 1996; 39: 643-649.
18. **Mehmet-Haznedar M, Buchsbaum M, Hazlett EA, Li Calzi EM, Cartwright Ch, Hollander E.** Volumetric analysis and three-dimensional glucose metabolic mapping of the striatum and thalamus in patients with autism spectrum disorders. *Am J Psychiatry* 2006; 163:1252-1263.
19. **Galuska L, Szakáil S Jr, Emri M, Oláh R, Vargás J, Garal I, Kollár J, Pataki I, Trón L.** PET and SPECT scans in autistic children. *Orv Hetil* 2002; 143: 1302-1304.
20. **Tuchman R.** Autism. *Neurol Clin N Am* 2003; 21:915-932.
21. **Guevara-Campos J, González-Guevara L.** Síndrome de Landau-Kleffner: Análisis de 10 casos en Venezuela. *Rev Neurol* 2007; 44:652-656.
22. **Canitano R, Zapella M.** Autism epileptiform regression. *Functional Neurology* 2006; 21(2): 97-101.
23. **Lerman-Sagie T, Leshinsky-Silver E, Waterberg N, Lev D.** Should autistic children be evaluated for mitochondrial disorders?. *J Child Neurol* 2004; 19: 379-381.

24. **Ueki I, Koga Y, Povalko N, Akita Y, Nishioka J, Yatsuga S, Fukiyama R, Matsuishi T.** Mitochondrial tRNA gene mutations in patients having mitochondrial disease with lactic acidosis. *Mitochondrion* 2006; 6:29-36.
25. **Fillano JJ, Goldenthal MJ, Rhodes CH, Marin-Garcia J.** Mitochondrial dysfunction in patients with hipotonia, epilepsy, autism and developmental delay: HEADD syndrome. *J Child Neurol* 2002; 17:435-439.
26. **DiMauro S.** Mitochondrial disease. *Biochim Biophys Acta* 2004; 1658:80-88.
27. **DiMauro S, Schon EA.** Mitochondrial respiratory-chain diseases. *N Engl J Med* 2003; 348:2656-2668.
28. **Pons R, Andreu AL, Checcarelli N, Vila MR, Engelstad K, Sue CM, Shungu D, Haggerty R, Vivo DC, DiMauro S.** Mitochondrial DNA abnormalities and autistic spectrum disorders. *J Pediatr* 2004; 144: 81-85.
29. **Ruiz-Pesini E, López-Gallardo E, Dahmani Y, Herrero MD, Solano A, Díez-Sánchez C, López-Pérez M, Montoya J.** Enfermedades del sistema de fosforilación oxidativa mitocondrial humano. *Rev Neurol* 2006; 43:416-424.
30. **Zecavati N, Spence SJ.** Neurometabolic disorders and dysfunction in autism spectrum disorders. *Curr Neurol Neurosci Rep* 2009; 9(2):129-136.