

p16^{INK 4a} and Ki-67 expression in human papilloma virus-related head and neck mucosal lesions.

Sibel Elif Gültekin¹, Burcu Sengüven¹, Jens Peter Klussmann² and Hans Peter Dienes³.

¹Gazi University, Faculty of Dentistry, Department of Oral Pathology. Ankara, Turkey.

²Giessen University, Faculty of Medicine, Department of Oto Rhino Laryngology. Giessen, Germany.

³University of Cologne, Faculty of Medicine, Institute for Pathology. Cologne, Germany.

Keywords: human papillomavirus, dysplasia, oral, p16^{INK 4a}, Ki-67.

Abstract. Human papilloma virus (HPV) is postulated as a risk factor in the etiology of some specific mucosal pathologies in the head and neck regions. Despite the frequent use of p16^{INK4a} as a surrogate marker for HPV-infection, there is still controversy with respect to its reliability. This study has been undertaken to assess the potential role of p16^{INK 4a} and Ki-67 expression in HPV-related lesions. The study was conducted on 71 specimens of oral, tonsillar and laryngeal lesions which comprised 25 dysplasia and 46 papilloma specimens. Specimens were immunohistochemically stained for p16^{INK4A} and Ki-67 proteins. HPV DNA was determined by one step multiplex polymerase chain reaction. HPV DNA was detected in 33.8% of all lesions. Tonsil and larynx lesions showed significant differences with oral lesions for HPV positivity ($p < 0.001$). p16^{INK 4a} over-expression was seen in 56.5% of papilloma and 60% of dysplasia specimens. HPV status showed a positive correlation with p16^{INK 4a} expression in tonsillar dysplasias ($p < 0.001$). p16^{INK 4a} expression may have a value as a marker in high risk HPV induced dysplasias, but not in low risk infected lesions. The proliferation index is not related to HPV-induced lesions and may be evaluated as an independent marker in head and neck pre-malignant lesions.

Expresión de p16^{INK 4a} y Ki-67 en las lesiones de cabeza y cuello relacionados con el virus del papilloma humano.

Invest Clin 2015; 56(1): 47 - 59

Palabras clave: virus del papiloma humano, displasia, oral, p16^{INK 4a}, Ki-67.

Resumen. El virus del papiloma humano (VPH) se postula como un factor de riesgo en la etiología de algunas patologías de la mucosa, específicas en las regiones de cabeza y cuello. A pesar de usar con frecuencia el p16^{INK4A} como un marcador sustituto para la infección por VPH, todavía existe controversia con respecto a su fiabilidad. Este estudio se ha llevado a cabo para evaluar el papel potencial de la expresión de p16^{INK 4a} y de Ki-67 en las lesiones relacionadas con el VPH. El estudio se realizó en 71 muestras de lesiones orales, tonsilares y laríngeas que comprendían 25 displasias y 46 especímenes de papiloma. Los especímenes fueron teñidos inmunohistoquímicamente para p16^{INK4a} y Ki-67. El ADN del VPH se determinó mediante una PCR multiplex de un paso. ADN del VPH se detectó en el 33,8% de todas las lesiones. Las lesiones de la amígdala y laringe mostraron diferencias significativas con lesiones orales para la positividad de VPH ($p < 0,001$). Sobre-expresión de p16^{INK 4a} se observó en 56,5% de las muestras de papiloma y 60% de las muestras de displasia. El estatus del VPH mostró una correlación positiva con la expresión de p16^{INK4a} en displasias tonsilares ($p < 0,001$). La expresión de p16^{INK4a} puede tener valor como marcador en las displasias inducidas por VPH de alto riesgo, pero no en las lesiones infectadas de bajo riesgo. El índice de proliferación no está relacionado con las lesiones inducidas por VPH y puede ser evaluado como un marcador independiente en las lesiones premalignas de la cabeza y del cuello.

Recibido: 01-08-2014 Aceptado: 13-11-2014

INTRODUCTION

Squamous cell carcinoma (SCC) is the most common malignancy of the head and neck (1). The development of one third of head and neck carcinoma is a two stage process; first potentially malignant lesions appear (dysplasia), then carcinoma develops (2). The most feared complication is clearly the development of squamous cell carcinoma. Estimates of the malignant alterations rate of oral dysplasia in the studies range widely between 8.9 to 17.5% (3). Head and neck carcinogenesis, manifested histologically as progressive squamous dys-

plasia, results from cumulative genetic and epigenetic alterations induced by exposure to carcinogenic agents, particularly alcohol and tobacco (4). Oncogenic human papilloma viruses (HPVs) have also been implicated as carcinogenic agents: Infection with HPV high-risk types is associated with the development of 25% of head and neck cancers (5). Despite histological criteria for the diagnosis of dysplasia, applying these criteria is difficult in some cases, fueling the search for diagnostic aids, particularly in identifying molecular correlates of carcinogenesis.

HPVs-associated oropharynx carcinomas have been postulated as distinct tumor

entities in terms of biological behavior and treatment outcome; whereas, in oral carcinomas it has not been well documented (2). For head and neck cancers, particularly SCC arising in the oropharynx, the detection of HPV-16 has been associated with improved survival and a better response to treatment, thus it can be categorized as a prognostic marker (3). HPV-16 sequences can be detected in DNA isolated from tissue samples by PCR either directly in tissue sections by *in situ* hybridization or indirectly by the detection of expression of p16 [CDKN2A] (4). Since the detection of high risk HPV in oropharyngeal carcinoma is correlated with its outcome, the expectation is that this biomarker will, in the future, be used to stratify patients into different treatment plans and in this way, avoid unnecessary overtreatment and incapacitating side effects (5).

The Ki-67 antigen is expressed in proliferating cells (in the G1, S, G2, and M phases), but not in resting cells (G0 phase). Therefore, the Ki-67 antigen is a proliferation marker whose appearance correlates with the presence and severity of the epithelial dysplasia. It has been suggested as a significant marker to recognize evolution of precancerous disease in the oral cavity and to improve the identification of the degree of dysplasia (6).

The squamous papillomas are benign, very common (2.5-3% of all oral biopsies) epithelial proliferations most caused by HPV (subtypes 2, 6, 11), resulting in papillary or verruciform lesions. Recurrence followed by surgical excision is uncommon and malignant transformation is very unlikely (7, 8).

The goal of this study was to evaluate the p16^{INK 4a} protein and Ki-67 expression profile in HPV related oral, tonsillar and laryngeal lesions with special reference to epithelial dysplasias. This study aimed to further understand the nature of dysplasia and

papilloma by cataloguing the HPV status and to compare them with p16^{INK 4a} over expression and proliferation indexes. For this purpose p16^{INK 4a} and Ki-67 combined immunohistochemistry staining and HPV-multiplex PCR was used to assess the concordance of these markers as first step bio-markers for the identification of HPV-associated with both, high and low-risk oral, tonsillar and laryngeal lesions.

MATERIALS AND METHODS

Tissue specimens

A total of 71 formalin fixed, paraffin-embedded oral, tonsillar and laryngeal biopsy specimens that had been taken for routine pathological diagnosis were obtained from the archives of the Gazi University Faculty of Dentistry Department of Oral Pathology, Ankara, Turkey and University of Cologne Pathology Institute, Cologne, Germany and approved by the Review Board of Gazi University and Local Ethics Committee in Cologne.

Haematoxylin and eosin stained sections were examined by two experienced histopathologists, to confirm the diagnosis and to evaluate the degree of dysplasia by light microscope, according to the World Health Organization histological criteria (9).

Of the 71 specimens, 25 corresponded to mild to severe degree dysplasias and 46 were papilloma lesions. Twelve of 25 dysplasia specimens were from the oral cavity, 9 and 4 were from tonsils and larynx, respectively. Of 46 papilloma specimens, 20 were oral and 26 were tonsillar and laryngeal lesions.

The patients' age ranged from 7 to 82 years, and there was a male / female ratio of 3:1.

Immunohistochemistry

Four μ m-thick sections were deparaffinized and rehydrated. p16^{INK4a}

(mouse monoclonal antibody, clone 16PO4, LabVision, Fremont, CA, USA) and anti-Ki67 (rabbit monoclonal antibody, clone /sp6, NeoMarker, USA) were used as primary antibodies. Staining was performed using the Dako TechMate 500 plus auto-stainer for p16^{INK 4a} antibody (DAB detection kit, DAKO).

For immunohistochemical detection of the proliferation marker Ki-67, the streptavidin biotin complex (Neomarkers Ultravision Detection system Anti-Polyvalent, HRP/DAB kit) method was used. After deparaffinization by xylene and rehydration with 96% ethanol, endogenous peroxides activity was blocked with 3% hydrogen peroxide in phosphate-buffered saline [phosphate-buffered saline (PBS), pH 7.6] for 10 min and rinsed with PBS. For antigen retrieval, the sections were boiled in citrate buffer [2.64 g/l sodium citrate, pH 6.0] for 15 min. Then the primary antibody anti-Ki67 was added and incubated for 2 hours at room temperature. The slides were overlaid with the secondary antibody (Biotinylated Goat Anti-Polyvalent, NeoMarker, USA) for 10 min. The immunoperoxidase labeling was performed; diaminobenzidine (DAB, Zymed, USA) was used as a chromogen for visualization of the antibody binding. Finally, the sections were counter stained with Harris's haematoxylin, cleared and mounted. A section of severe cervical squamous dysplasia was used as a positive control for p16^{INK 4a} and tonsil tissue for Ki67.

Scoring of immunohistochemical staining

Strong brown nuclear staining as well as strong cytoplasmic staining was considered positive for p16^{INK 4a} expression. p16^{INK 4a} immunostaining was graded and scored on whole sections as follows (10).

- Score 0 degree: negative, staining pattern: negative (0-5% of nuclei and cytoplasm positive),

- Score 1 degree: low, staining pattern: sporadic (5-10% of nuclei and cytoplasm weak and scattered positivity),
- Score 2 degree: moderate, staining pattern: focal (> 10-30% of labeled nuclei and cytoplasm strongly positive, spreading one tissue area),
- Score 3 degree: high, staining pattern: diffuse (>30-85% labeled cells with strong positivity, spreading in several tissue areas)

The localization of Ki-67 immunoreactivity within tissues was evaluated and the staining pattern was recorded before cell counting. The cell with brown nuclear staining was considered as positive for Ki-67, regardless of their intensity. Scoring Ki-67 reactivity was carried out using a standard light microscope on one high power field (6). The proliferation index (PI) for each section was expressed as the percentage of positive stained cells per total number of nucleated epithelial cells. Grades 1, 2 and 3 were given when the PI index was below 5%, 5-30% and greater than 30%, respectively.

DNA extraction

Genomic DNA was extracted from four sections with 7.5 μm thickness of paraffin embedded tissue, using the DNA extraction kit from Purgene DNA Isolation Kit (Gentra Systems, Minneapolis, MN) according to the instructions of the manufacturer. DNA integrity was confirmed by β -Globin gene PCR as described previously (11).

HPV detection by PCR

HPV detection was performed using the GP5⁺/GP6⁺ primer set (*2) by one step multiplex PCR (QIA-GEN PCR Amplification kit, Hilden, Germany), with around 140-150 amplicon in the L1 HPV gene, which was described earlier (3). Briefly, PCR amplification was done in a 25- μL volume, and included 12.5 μL Qiagen multi-

plex kit, 8 μ L water, 1 μ L of each HPV type 3' and 5' primers and 2.5 μ L extracted DNA. PCR was performed in a thermal cycler (Biometra, Göttingen, Germany) starting with a pre-incubation at 95°C for 15 minutes, then followed by 1 min denaturation at 95°C, 1.5 min annealing at 45°C for 45 cycles, 1.5 min elongation at 72°C and 10 min incubation at 72°C.

Sequencing of PCR products and comparison of the obtained sequences performed human papilloma virus typing by database searches (NCBI blast). Direct sequence analysis of purified PCR products (QIAquick gel extraction kit, Qiagen, Hilden, Germany) was carried out with an Applied Biosystems 3730 capillary DNA sequencer using the Taq FS Big-Dye-Terminator cycle sequencing method (PE Applied Biosystems, Weiterstadt, Germany).

Statistical analysis

Mann-Whitney U and Kruskal Wallis tests were used to test differences among the groups. Correlation was evaluated by Spearman's correlation test. P values smaller than 0.05 were regarded as statisti-

cally significant. All statistical analysis was performed using SPSS 16.0 (Chicago, IL, USA).

RESULTS

Histological grading for 25 specimens of dysplasia in this study showed there were seven specimens with mild dysplasia, four specimens with moderate dysplasia and 14 specimens with severe dysplasia. The vast majority of tonsil dysplasia cases were severe dysplasias (78%) (Table I).

HPV status

HPV DNA was detected in 24 of 71 lesions (33.8%) (Table II). In dysplasia lesions, tonsils were the predominant sites for HPV infection (77.7%) ($p < 0.001$). The larynx showed highest HPV positivity in papilloma lesions (61.5%) ($p < 0.01$). Oral dysplasia specimens were HPV negative. When papilloma and dysplasias were compared on HPV positivity, regardless of their anatomical location, significant differences were not found between the two lesions.

TABLE I
HISTOLOGICAL GRADING OF DYSPLASIA LESIONS

	HPV (-) (n)	HPV6 (+) (n)	HPV11 (+) (n)	HPV16 (+) (n)	HPV +/-%	p
Oral Papilloma (n: 20)	17	3	0	0	15	0.006*
Larynx Papilloma (n: 13)	5	4	4	0	61.5	0.123
Tonsil Papilloma (n: 13)	9	0	0	4	30.8	0.286
Oral Dysplasia (n: 12)	12	0	0	0	0	0.011*
Larynx Dysplasia (n: 4)	2	1	0	1	50	0.336
Tonsil Dysplasia (n: 9)	2	0	0	7	77.7	0.000*

* $p < 0.05$

TABLE II
HPV STATUS OF THE LESIONS BY LOCALISATION

Location	Mild (Grade 1)		Moderate (Grade 2)		Severe (Grade 3)	
	n	%	n	%	n	%
Oral (n: 12)	3	25	4	33	5	42
Larynx (n: 4)	2	50	0	0	2	50
Tonsil (n: 9)	2	22	0	0	7	78

Tonsillar and laryngeal papilloma and dysplasia lesions showed a significant difference with oral lesions for HPV positivity, respectively ($p < 0.05$, $p < 0.001$).

Among the 24 HPV positive specimens, the most frequent detected HPV type was HPV-16 (50%), followed by HPV-6 (33.3%) and HPV-11 (16.7%). Low risk type HPV DNA (HPV-6/11) was found in one (4%) of 25 dysplasia specimens and in 12 (26.08%) of 46 papillomas. HPV-16 was the high risk HPV DNA that was detected in 8 (32%) of 25 dysplasia specimens and in 4 (8.6%) of 46 papilloma specimens. Tonsils were the most frequent site with HPV 16 (91.6%), whereas larynx was for the HPV 11(100%).

p16^{INK 4a} status

p16^{INK 4a} over expression was seen in 26 of 46 (56.5%) papilloma and 15 of 25 (60%) dysplasia specimens.

The dysplasia specimens demonstrated a high degree (score 3) staining pattern, which is, characterized diffuse nuclear and cytoplasmic staining of the cells in all layers of epithelium. The majority of tonsillar and laryngeal specimens with dysplasia showed p16^{INK 4a} positivity with high degree, score 3 and 2 (10 of 13 specimens; 7%), whereas oral dysplasia had lower p16^{INK 4a} protein expression (3 of 12; 25%) ($p = 0.001$) (Fig. 1).

In papilloma specimens, p16^{INK 4a} expression was higher in tonsillar and laryngeal lesions (18 of 26 specimens; 69.2%)

with special reference to larynx than oral lesions (9 of 13 specimens; 62.2%) ($p < 0.01$).

Table III shows that the HPV status was associated with p16^{INK 4a} expression in dysplasia lesions ($p < 0.001$, $\rho = 0.823$). HPV status showed a statistically significant positive correlation with p16^{INK 4a} expression in tonsillar dysplasias ($p < 0.001$, $\rho = 0.992$) whereas negative correlation was found in larynx papilloma lesions ($p < 0.05$, $\rho = -.654$).

Ki-67 status

Ki-67 expression was observed in all layers of epithelium in dysplasia and papilloma lesions, out of four specimens (Fig. 2).

The higher proliferation index was seen in dysplasia specimens with 17.40 mean PI value, which was 8.37 in papilloma specimens. The difference between groups was statistically significant ($p < 0.05$). When Ki-67 expression scores of both lesions were compared according to anatomical locations, the significant difference was seen between laryngeal and tonsillar papillomas ($p < 0.05$). There was no statistical significance on Ki-67 expression scores between oral and oropharyngeal lesions.

PI grading displayed no correlation with HPV in both lesions in oral cavity and tonsillar and laryngeal, where p16^{INK 4a} over expression was correlated with PI grading in oral papilloma specimens ($p = 0.05$, $\rho = 0.408$).

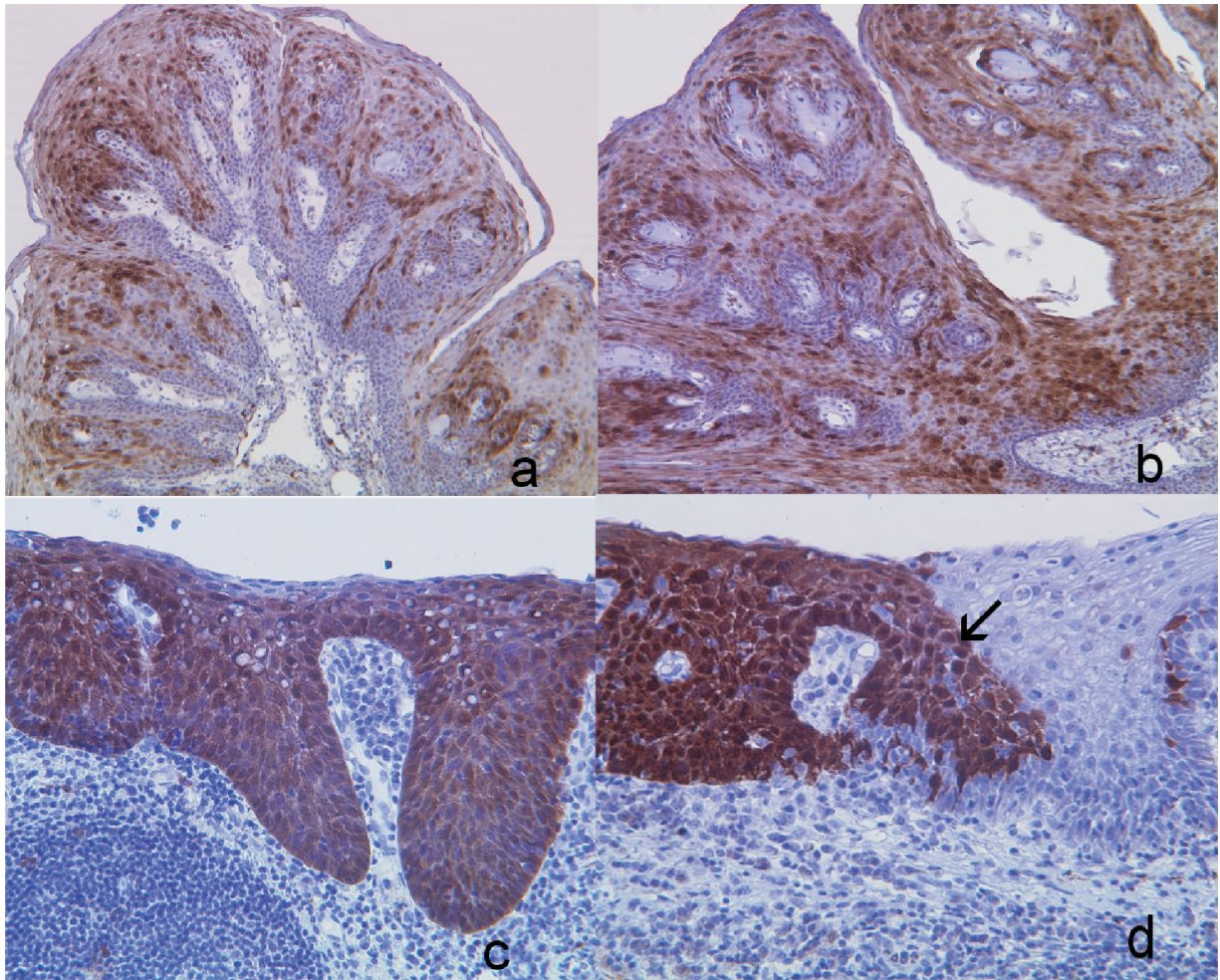


Fig. 1. Representative examples of p16^{INK 4a} immunohistochemical staining patterns of papilloma and dysplasia lesions.

- a: Focal (score 2) p16^{INK 4a} staining in tonsillar papilloma lesion (DAB, x100).
 b: Diffuse (score 3) p16^{INK 4a} staining in laryngeal papilloma lesion (DAB, x100).
 c: Diffuse (score 3) p16^{INK 4a} staining in tonsillar dysplasia lesion (DAB, x100).
 d: The p16^{INK 4a} exclusively highlights the dysplastic epithelium (arrow head) (DAB, x40).

DISCUSSION

SCC of oral and oropharyngeal regions is the end-point of a multistep process after a long dysplastic period in most cases. Some of the molecular changes that are associated with the dysplastic cascade have been described, but the underlying molecular defects are essentially not known (12, 13). Oropharyngeal SCC to a higher degree and oral SCC to a lesser degree are found associated with HPV infection (14). To

date, the presence of HPV is accepted as a powerful independent predictor of response to therapy and overall survival in patients with head and neck SCC. The methodology for detection of this biomarker is crucial. Since it may not be sufficient to simply score tumor samples as HPV positive or negative (15, 16), an indirect measurement such as detection of p16^{INK 4a} has been postulated as a surrogate marker for HPV related oropharyngeal carcinomas with special reference to tonsils (17). However, the

TABLE III
P16 AND Ki-67 EXPRESSIONS ACCORDING TO THE STATUS OF HPV

HPV Status	p16 ^{INK 4a} over-expression grades				PI grades (Ki67)***			
	0	1	2	3	0	1	2	3
Oral Papilloma HPV (+) (n: 3)	2 (66.6%)	1 (33.3%)	0	0	0	1 (33.3%)	2 (66.6%)	0
Oral Papilloma HPV (-) (n: 17)	10 (58.8%)	6 (35.2%)	1 (5.8%)	0	4 (23.5%)	4 (23.5%)	9 (52.9%)	0
Larynx Papilloma HPV(+)* (n: 8)	4 (50%)	0	4 (50%)	0	0	1 (12.5%)	7 (87.5%)	0
Larynx Papilloma HPV (-) (n: 5)	0	1 (20%)	3 (60%)	1 (20%)	0	2 (40%)	3 (60%)	0
Tonsil Papilloma HPV (+) (n: 4)	1 (25%)	0	3 (75%)	0	0	4 (100%)	0	0
Tonsil Papilloma HPV (-) (n: 9)	3 (33.3%)	3 (33.3%)	3 (33.3%)	0	1 (11.1%)	5 (55.5%)	2 (22.2%)	1 (11.1%)
Oral Dysplasia HPV (+) (n:0)	0	0	0	0	0	0	0	0
Oral Dysplasia HPV (-) (n:12)	9 (75%)	2 (16.6%)	1 (8.3%)	0	1 (8.3%)	2 (16.6%)	7 (58.3%)	2 (16.6%)
Larynx Dysplasia HPV (+) (n:2)	0	1 (50%)	0	1 (50%)	0	1 (50%)	0	1 (50%)
Larynx Dysplasia HPV (-) (n:2)	1 (50%)	0	1 (50%)	0	0	0	2 (100%)	0
Tonsil Dysplasia HPV (+)** (n:7)	0	0	0	7 (100%)	0	3 (42.8%)	2 (28.5%)	2 (28.5%)
Tonsil Dysplasia HPV (-) (n:2)	0	1 (50%)	1 (50%)	0	0	2 (100%)	0	0

* HPV- p16^{INK 4a} status in larynx papilloma (p: 0.015, rho: -.654). ** HPV- p16^{INK 4a} status in tonsillar dysplasia (p: 0.000, rho: .992). *** Ki67- p16^{INK 4a} status in oral papilloma (p: 0.037, rho: .408).

role of p16^{INK 4a} as a biomarker has not been clearly shown in both, premalignant and malignant lesions of oral cavity and larynx (18, 19). Thus, we intended to evaluate the p16^{INK 4a} and Ki-67 expression profile in HPV related oral and tonsillar and laryngeal benign and dysplastic lesions.

Moreover, despite the body of studies, reliable markers for progression of high risk HPV infected epithelium to malignancy are not yet available (14). In cervix lesions, both Ki-67 and p16^{INK 4a} are shown as potential predictive markers for progression towards malignancy whereas, in head and

neck lesions, their utility in the prediction of risk on malignant transformation remains unknown (20). There should be more evidence from studies with significant number of cases in order to prove a relationship between HPV infection and oral and oropharyngeal SCC.

In the present study HPV DNA was detected in 24 of all 71 lesions (33.8%). Although the reported rates of detection HPV DNA in oral and oropharyngeal SCC range from 0 to 100% (21), it is generally accepted that HPV DNA is detected in about 26% of oral and oropharyngeal SCCs (22);

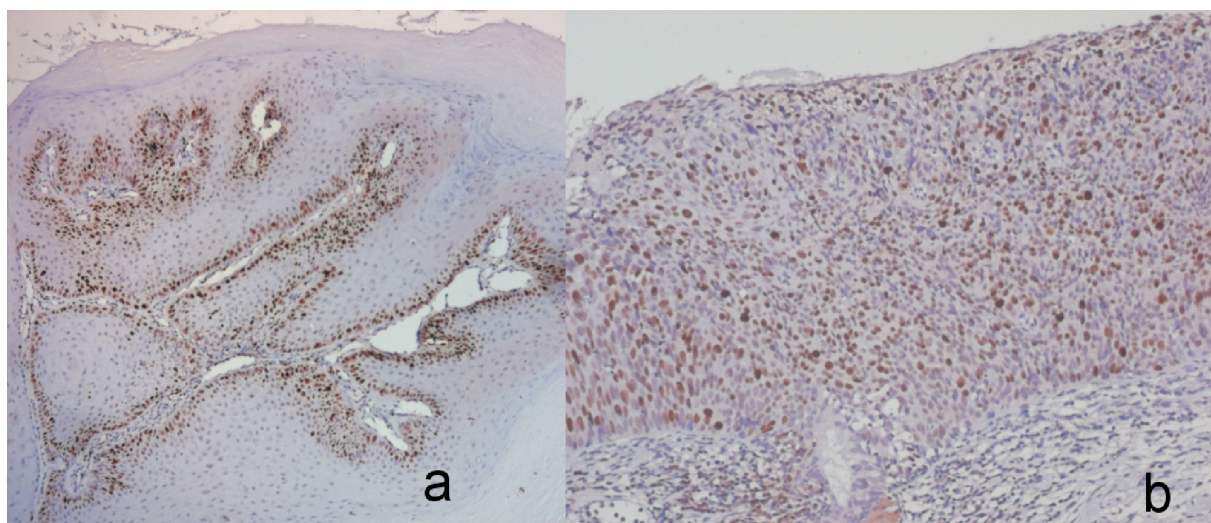


Fig. 2. Representative examples of Ki-67 immunohistochemical staining in oral and oropharyngeal papilloma and dysplasia lesions.

a: Ki-67 staining (score 2) in oral papilloma lesion (DAB, x 40).

b: Diffuse Ki-67 staining in tonsillar dysplasia (DAB, x 200).

and as in this study, particularly oropharyngeal neoplasms contain HPV DNA more frequently than any neoplasm of the head and neck.

In the present study, tonsils were the predominant sites for HPV infection in dysplasia lesions (77.7%) ($p < 0.001$). Oral dysplasia specimens were all HPV negative. HPV infection was significant in both tonsillar and laryngeal papillomas and dysplasias. Data appearing in the literature have provided strong evidence that HPVs may be cause of epithelial lesions, particularly those of the oropharynx (22). Among all the head and neck carcinomas, tonsillar carcinoma has the highest prevalence of HPV-16 infection suggesting that the virus had a special affinity to tonsillar epithelium. The decreased presence of HPV in oral lesions is consistent with a large series of studies today. In order to make clear the lower incidence of HPV in oral lesions than in oropharyngeal lesions, issues such as the age of the patient, the time of sexual transmission of HPV, the detection methods and the source of DNA have been discussed (11).

HPV presence has been displayed in many studies related with both dysplastic and normal epithelium of oral mucosa, whereas some other data showed no statistically significant relationship between HPV and oral dysplasia (23). Nevertheless, because HPV infections remain frequently for only a brief time, absence of HPV DNA from any dysplastic tissue does not exclude the theoretical chance of it having played role in the initiation of the carcinogenesis. In the present study, significant HPV positivity was found in tonsillar and laryngeal benign and potentially malignant lesions than the lesion located in oral cavity ($p < 0.05$, $p < 0.001$). The HPV types infecting mucosa differ from HPV types infecting skin and it has been stated that this difference is the result of ubiquitous transcription factors working in the host cell, which determines the cell type specific expression (24). Some studies have shown a higher prevalence of HPV in OSCC and interestingly most of them from non-European countries. Different HPV susceptibilities in different ethnicities/geographic re-

gions or due to different HPV detection methods may explain the diversity (25).

Similar to other studies, HPV-16, known to be associated with malignancy, was the most common type detected in positive tonsillar and laryngeal dysplasias (88.8%) with special reference to tonsils (100%) (26, 27). Moreover, one of the striking points of our results was the presence of the HPV-16 in all HPV positive tonsillar papillomas. Depending on the outcome of this data we may speculate that HPV-16 is the unique type of HPV which displays tropism to tonsillar epithelium. This is supported by the studies which found HPV-16 positive DNA in normal tonsillar mucosa. Most probably, HPV-16 infected tonsillar papillomas may progress in premalignant form and malignancy, eventually.

In the current study, HPV-11 was detected mostly in positive laryngeal papillomas (100%) which are in concordance with the other studies (28, 29). Despite the fact that HPV-11 is among the most commonly detected type of HPV, neither was found in the laryngeal dysplasia samples, confirming the role of this viral type as precursors of mostly benign papillomas rather than malignancies.

PI was higher in dysplasia specimens than papilloma specimens in both oral and tonsillar and laryngeal lesions ($p < 0.05$) in the present study which might explain no malignant transformation in papillomas. Therefore, papillomas have a lower possibility to accumulate genetic mutations than the epithelial dysplasia, consequently, a lower chance to have malignant transformation. Malignant or premalignant phenotypes could be a result of the higher risk of cells exposing mutational factors during the cell cycle.

Our results are in line with the other recent reports (14, 19, 20). In tonsillar dysplasia lesions, we found a strong correlation between p16^{INK 4a} over expression and

HPV 16 positivity ($p < 0.001$, $\rho = .992$). Other recent study showed approximately 60% of oropharyngeal squamous cell cancers are HPV positive (4). Over expression of p16^{INK 4a} in dysplastic oropharyngeal lesions has been found to be related with high risk HPV. HPV positive tumors are characterized by the loss of pRb and Cyclin D1 expression and by over-expression of p16^{INK 4a}. The hypothesis of blocking the Rb protein by viral oncoprotein E7 and the loss of p16^{INK 4a} inhibition by Rb protein is to be responsible for that result. p16^{INK 4a} has been identified as a biomarker for HPV-induced dysplastic lesions of the cervix and it has been suggested that it may be a useful diagnostic aid for these lesions (25, 30). The p16^{INK 4a} immunoreactivity we showed in this study pointed out that HPV status, which ascertained by p16^{INK 4a} in dysplasia lesions, may be used as a surrogate marker for oral and oropharyngeal lesion as well. This result also suggests that not only demonstrating the HPV infection, but also showing the over expression of p16^{INK 4a} are needed to confirm relevant viral oncogene expression in dysplastic lesions. In addition, 40% of all dysplasias were negative for both HPV DNA and for over-expression of p16^{INK 4a}. This finding may help to understand any role of HPV in the development of oral and oropharyngeal squamous dysplasia. Therefore, we conclude that HPV plays an important role in most of the oropharyngeal dysplasias. We demonstrated that all HPV-16 positive tonsil and larynx dysplasias showed p16^{INK 4a} over expression.

In our study, the higher proliferation index was seen in dysplasia specimens with 17.40 mean PI value than papilloma specimens (PI: 8.37), the difference between the groups were statistically significant ($p < 0.05$). Increased proliferation index has been reported to be an important indicator in malignant progression. However, Ki-67,

alone, appears to be not suitable as a biomarker for showing the risk of malignant progression both in benign and dysplastic lesions. On the other hand, it has been used to show predictive and prognostic significances for years and now it is well known that as p16^{INK 4a}, the immunohistochemical expression of Ki-67 is increased with the degree of dysplasia (6).

Our study is a multi-center cohort to examine the role of a surrogate marker of HPV, p16^{INK 4a} oncoprotein expression in oral and oropharyngeal region. The differences of HPV presences between two anatomical sites may arise due to the fact that the study samples were collected from two different geographies, since, it is very well known that cultural habits, ethnicity and age, can influence the frequency of the HPV transmission (25).

In the present study, oral and laryngeal dysplasias were not associated with HPV infection and p16^{INK 4a} over expression, with only a high histopathological grade of dysplasia of tonsils significantly associated with p16^{INK 4a} expression. This study has also correlated the detection of p16^{INK 4a} protein with HPV DNA in oropharyngeal lesions. Nevertheless, this was a retrospectively collected study so; the prospective collection, with more cases and follow-up to show the risks of malignant transformation in different locations would be more encouraging for clinical trials.

ACKNOWLEDGEMENT

The author, SE Gültekin is supported by TUBITAK (Turkey)-DFG (Germany) Scientific Exchange Program (*Grant no: 2006-2225*). The authors also thank Dr. Emre Barış for his excellent help on Spanish writing.

REFERENCES

1. **Parkin DM, Bray F, Ferlay J, Pisani P.** Global cancer statistics, 2002. *CA Cancer J Clin* 2005; 55(2):74-108.
2. **Mehanna H, Olaleye O, Licitra L.** Oropharyngeal cancer - is it time to change management according to human papilloma virus status? *Curr Opin Otolaryngol Head Neck Surg* 2012; 20(2):120-124.
3. **Gillison ML, Lowy DR.** A causal role for human papillomavirus in head and neck cancer. *Lancet* 2004; 363(9420):1488-1489.
4. **Robinson M, Sloan P, Shaw R.** Refining the diagnosis of oropharyngeal squamous cell carcinoma using human papilloma-virus testing. *Oral Oncol* 2010; 46(7):492-496.
5. **Mehanna HM, Rattay T, Smith J, McConkey CC.** Treatment and follow-up of oral dysplasia - a systematic review and meta-analysis. *Head & Neck* 2009; 31(12): 1600-1609.
6. **Nam EJ, Kim JW, Hong JW, Jang HS, Lee SY, Jang SY, Lee DW, Kim SW, Kim JH, Kim YT, Kim S, Kim JW.** Expression of the p16 and Ki-67 in relation to the grade of cervical intraepithelial neoplasia and high-risk human papillomavirus infection. *J Gynecol Oncol* 2008; 19(3):162-168.
7. **Mannarini L, Kratochvil V, Calabrese L, Gomes Silva L, Morbini P, Betka J, Benazzo M.** Human Papilloma Virus (HPV) in head and neck region: review of literature. *Acta Otorhinolaryngol Ital* 2009; 29(3):119-126.
8. **Pec J, Filo V, Straka S, Baska T, Adamicova K, Pec M.** Human papilloma virus infection in the oral cavity—a source of infection. *J Eur Acad Dermatol Venereol* 1998; 10(3):275-277.
9. **Tilakaratne WM, Sherriff M, Morgan PR, Odell EW.** Grading oral epithelial dysplasia: analysis of individual features. *J Oral Pathol Med* 2011; 40(7):533-540.
10. **Klaes R, Friedrich T, Spitkovsky D, Ridder R, Rudy W, Petry U, Dallenbach-Hellweg G, Schmidt D, von Knebel Doeberitz M.** Overexpression of

- p16(INK4A) as a specific marker for dysplastic and neoplastic epithelial cells of the cervix uteri. *Int J Cancer* 2001; 92(2):276-284.
11. Klussmann JP, Weissenborn SJ, Wieland U, Dries V, Kolligs J, Jungheuling M, Eckel HE, Dienes HP, Pfister HJ, Fuchs PG. Prevalence, distribution, and viral load of human papillomavirus 16 DNA in tonsillar carcinomas. *Cancer* 2001; 92(11):2875-2884.
 12. McGregor F, Muntoni A, Fleming J, Brown J, Felix DH, MacDonald DG, Parkinson EK, Harrison PR. Molecular changes associated with oral dysplasia progression and acquisition of immortality: potential for its reversal by 5-azacytidine. *Cancer Res* 2002; 62(16):4757-4766.
 13. Zhang L, Rosin MP. Loss of heterozygosity: a potential tool in management of oral premalignant lesions? *J Oral Pathol Med* 2001; 30(9):513-520.
 14. Feller L, Wood NH, Khammissa RA, Lemmer J. Human papillomavirus-mediated carcinogenesis and HPV-associated oral and oropharyngeal squamous cell carcinoma. Part 2: Human papillomavirus associated oral and oropharyngeal squamous cell carcinoma. *Head Face Med* 2010; 6:15.
 15. Braakhuis BJ, Bloemena E, Leemans CR, Brakenhoff RH. Molecular analysis of surgical margins in head and neck cancer: more than a marginal issue. *Oral Oncol* 2010; 46(7):485-491.
 16. Braakhuis BJ, Brakenhoff RH, Leemans CR. Gene expression profiling in head and neck squamous cell carcinoma. *Curr Opin Otolaryngol Head Neck Surg* 2010; 18(2):67-71.
 17. Isayeva T, Li Y, Maswahu D, Brandwein-Gensler M. Human papillomavirus in non-oropharyngeal head and neck cancers: a systematic literature review. *Head Neck Pathol* 2012; 6 (Suppl 1):104-120.
 18. Biron VL, Mohamed A, Hendzel MJ, Alan Underhill D, Seikaly H. Epigenetic differences between human papillomavirus-positive and -negative oropharyngeal squamous cell carcinomas. *J Otolaryngol Head Neck Surg* 2012; 41 (Suppl 1):S65-70.
 19. Lewis JS, Jr. p16 Immunohistochemistry as a standalone test for risk stratification in oropharyngeal squamous cell carcinoma. *Head Neck Pathol* 2012; 6 (Suppl 1):75-82.
 20. Nasser W, Flechtenmacher C, Holzinger D, Hofele C, Bosch FX. Aberrant expression of p53, p16INK4a and Ki-67 as basic biomarker for malignant progression of oral leukoplakias. *J Oral Pathol Med* 2011; 40(8):629-635.
 21. Allen CT, Lewis JS, Jr., El-Mofty SK, Haughey BH, Nussenbaum B. Human papillomavirus and oropharynx cancer: biology, detection and clinical implications. *Laryngoscope* 2012; 120(9):1756-1772.
 22. Bleyer A. Cancer of the oral cavity and pharynx in young females: increasing incidence, role of human papilloma virus, and lack of survival improvement. *Semin Oncol* 2009; 36(5):451-459.
 23. Syrjänen S, Lodi G, von Bültzingslöwen I, Aliko A, Arduino P, Campisi G, Challacombe S, Ficarra G, Flaitz C, Zhou HM, Maeda H, Miller C, Jontell M. Human papillomaviruses in oral carcinoma and oral potentially malignant disorders: a systematic review. *Oral Dis* 2011; 17 (Suppl 1):58-72.
 24. Pradhan SA, Mulherkar R, Pai PS. Human papilloma virus and squamous cell carcinomas of the head and neck. *Natl Med J India* 2001; 14(5):284.
 25. Feller L, Lemmer J. Oral leukoplakia as it relates to HPV infection: A Review. *Int J Dent* 2012; 2012: 540-561.
 26. Xi LF, Koutsky LA, Castle PE, Edelstein ZR, Meyers C, Ho J, Schiffman M. Relationship between cigarette smoking and human papilloma virus types 16 and 18 DNA load. *Cancer Epidemiol Biomarkers Prev* 2009; 18(12):3490-3496.
 27. Wang Z, Dong J, Eyzaguirre EJ, Tang WW, Eltorky MA, Qiu S. Detection of human papilloma virus subtypes 16 and P16(ink4a) in invasive squamous cell carcinoma of the fallopian tube and concomitant squamous cell carcinoma in situ of the cervix. *J Obstet Gynaecol Res* 2009; 35(2):385-389.

-
28. **Azzimonti B, Hertel L, Aluffi P, Pia F, Monga G, Zocchi M, Landolfo S, Gariglio M.** Demonstration of multiple HPV types in laryngeal premalignant lesions using polymerase chain reaction and immunohistochemistry. *J Med Virol* 1999; 59(1): 110-116.
 29. **Dickens P, Srivastava G, Loke SL, Larkin S.** Human papillomavirus 6, 11, and 16 in laryngeal papillomas. *J Pathol* 1991; 165(3):243-246.
 30. **Wang J, Li J, Huang H, Fu Y.** Detection of the E7 transform gene of human papilloma virus type 16 in human oral squamous cell carcinoma. *Chin J Dent Res* 1998; 1(3): 35-37.