

Fibrolipomatous hamartoma of the median nerve: a case report and literature review.

You-Ting Dang¹, Xue-Hai Ou², Qiang Wang², Yun-Ping Zhou², Deng-Ke Wei² and Fei Xie²

¹Department of Pediatric Orthopedics, Honghui Hospital, Xi'an Jiaotong University, Xi'an, Shaanxi, China.

²Department of Hand Surgery, Honghui Hospital, Xi'an Jiaotong University, Xi'an, Shaanxi, China.

Keywords: fibrolipomatous hamartoma; the median nerve; the index finger; surgery; oncology.

Abstract. Fibrolipomatous hamartoma (FLH) of the nerve, also known as lipomatosis of the nerve, neurofibrillary lipomatous lesion, or intraneural lipoma, is a rare benign soft tissue tumor which mainly occurs in the nerves of the upper limb, especially in the median nerve. In April 2021, a 30-year-old male patient was secondly admitted to our hospital and underwent his third surgery, due to the recurrence of a mass and pain in the right palm, noticeable swelling and numbness of the right index and ring fingers, and limited flexion and extension activities of the right ring finger. He first visited our hospital in December 2017 due to a mass and pain in the right palm and swelling and numbness of the right index and ring fingers. When the clinician asked for the patient medical history, his parents stated that his right middle finger was swollen after birth. When the patient was ten years old; he was diagnosed with “macroductyly” at the local county hospital, not in our hospital, and subsequently, the middle finger was amputated at the metacarpophalangeal joint level at the local county hospital. The postoperative pathological examination was not performed at that time, which was the first surgery the patient received. FLH is clinically rare, and its exact epidemiology and etiology are poorly understood. FLH is highly suspected in cases where a painless mass is present in the wrist, combined with macroductyly. Magnetic resonance imaging and pathological examination are helpful in clarifying the diagnosis. Although FLH is a benign tumor, an individual treatment plan is the best choice according to the severity of the patient's symptoms. Therefore, further exploration and understanding of this disease by clinicians radiologists, and pathologists is necessary.

Hamartoma fibrolipomatoso del nervio mediano: reporte de un caso y revisión de la literatura.

Invest Clin 2022; 63 (4): 400 – 413

Palabras clave: hamartoma fibrolipomatoso; nervio mediano; dedo índice; cirugía; oncología.

Resumen. El hamartoma fibrolipomatoso (FLH) del nervio, también conocido como lipomatosis del nervio, lesión neurofibrilar lipomatosa, o lipointra-neural, es un tumor benigno de tejido blando poco frecuente, que se presenta principalmente en los nervios del miembro superior, especialmente en el nervio mediano. En abril de 2021, un paciente masculino de 30 años fue ingresado por segunda vez en nuestro hospital y sometido a su tercera cirugía debido a la recurrencia de una masa y dolor en la palma derecha, evidente hinchazón y entumecimiento de los dedos índice y anular derecho y limitadas actividades de flexión y extensión del dedo anular derecho. En diciembre de 2017, visitó por primera vez nuestro hospital debido a una masa y dolor en la palma derecha, y a la hinchazón y entumecimiento de los dedos índice y anular derecho. Cuando el clínico preguntó la historia clínica del paciente, sus padres declararon que su dedo medio derecho estaba hinchado después del nacimiento, y cuando el paciente tenía 10 años, fue diagnosticado con “macroductilia” en el hospital local del condado, no en nuestro hospital. Posteriormente, el dedo medio fue amputado a nivel de la articulación metacarpofalángica en el hospital comarcal local, pero no se realizó la patología postoperatoria en ese momento, siendo ésta la primera cirugía a la cual se sometió el paciente. La FLH es clínicamente rara, y su epidemiología y etiología exactas no se entienden bien. En los casos que presentan una masa indolora en la muñeca, combinada con macroductilia, se sospecha de FLH. La resonancia magnética y la patología son útiles para aclarar el diagnóstico. Aunque la FLH es un tumor benigno, el plan de tratamiento individual es la mejor opción de acuerdo con la gravedad de los síntomas del paciente. Por lo tanto, es necesaria una mayor exploración y comprensión de esta enfermedad por parte de médicos, radiólogos y patólogos.

Received: 24-04-2022

Accepted: 10-05-2022

INTRODUCTION

Fibrolipomatous hamartoma of the nerve (FLH), also known as lipomatosis of the nerve, neurofibrillary lipomatous lesion, or intraneural lipoma, is a rare benign soft tissue tumor, which mainly occurs in the nerves of the upper extremity, especially in the median nerve and its branches¹⁻³. In addition,

a few occur in the ulnar nerve, radial nerve or sural nerve, and a few are accompanied by macroductyly³. Clinically, it should be avoided to be confused with simple lipoma and neurofibromas. Magnetic resonance imaging (MRI) remains the gold standard for the diagnosis of FLH. The pathological morphology of FLH is characterized by the proliferation of fibrofatty tissues around the nerve, infil-

tration of the epineurium and perineurium, and obvious thickening and deformation of the affected nerve. As we know, there are few reports on fibrolipomatous hamartoma of the peripheral nerve in domestic and international literature. In this paper, we report a rare case of fibrolipomatous hamartoma of the median nerve and performed a literature review on this condition.

Case presentation

This study was conducted in accordance with the declaration of Helsinki and approved by the Ethics Committee of Honghui Hospital, Xi'an Jiaotong University. Written informed consent to publish the clinical details and images of the patient was obtained.

In April 2021, a 30-year-old male patient was secondly admitted to our hospital due to the recurrence of a mass and pain in the right palm, obvious swelling and numbness of the right index finger and ring finger, and limited flexion and extension activities of the right ring finger.

In December 2017, he came to our hospital for the first time because of a mass and pain in the right palm, and swelling and

numbness of the right index finger and ring finger. When the clinician asked about the patient's medical history, his parents stated that his right middle finger was swollen after birth, and when the patient was 10 years old, he was diagnosed with "macroductyly" in the local county hospital, not in our hospital. Subsequently, the middle finger was amputated at the metacarpophalangeal joint level in the local county hospital, which was the first surgery the patient received. The post-operative pathological examination was not performed at that time. None of the family members had this kind of disease.

In December 2017, he underwent his second surgery in our hospital. The preoperative physical examination in our hospital showed that the right middle finger was absent. The whole right index finger was significantly swollen and had a wide nail. The right ring finger, proximal to the right palm was swollen, there was a soft tissue mass of 10cm*3-5cm on the radial side of the right palm and the palmar side of the right wrist and a mass of 2cm*1cm on the ulnar side of the distal segment of the right thumb (Figs. 1A and 1B), The flexion and extension

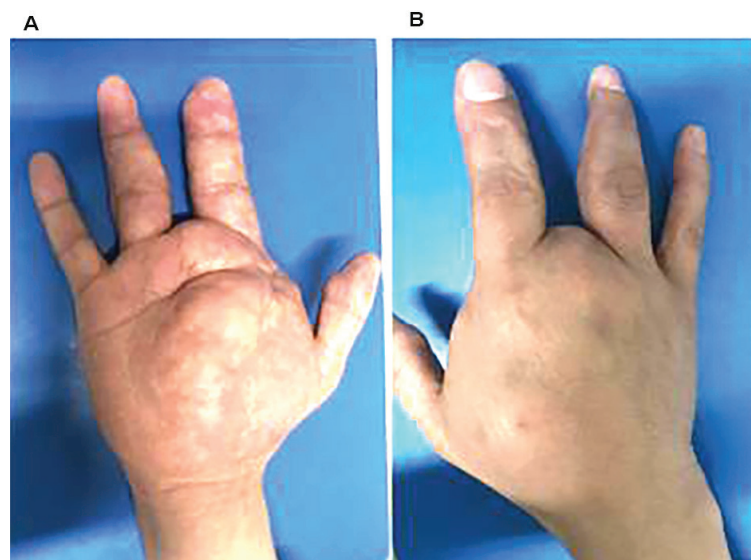


Fig. 1. Preoperative volar side of the right hand in A and dorsal side of the right hand in B showing the absent right middle finger, a soft tissue mass on the right palm, significantly swollen right index finger body, and partially swollen right ring finger.

activities of the right index finger and ring finger were limited, accompanied by skin numbness, the right hand was restricted in making a fist, and the peripheral blood flow was normal. The auxiliary examinations, including B-scan ultrasonography, X films and computerized tomography (CT), were performed. The B-scan ultrasonography revealed intense hyperechogenicity in the soft tissue of the volar aspect of the right hand (Fig. 2). The X films revealed the absent right middle finger, the deformation of the third metacarpus head with decreased bone density, and the deformation of the articular surface of the middle phalanx head in the index finger (Figs. 3A and 3B). The CT revealed a solid lesion in the soft tissue of the right palm (Fig. 4).

Brachial plexus nerve blocking anesthesia was used. An S-shaped incision was made on the volar side of the right forearm and the right palm. Intraoperatively, a great amount of granular hyperplastic adipose tissue was observed (Figs. 5A, 5B, 5C, and 5D). The median nerve was dissected from the proximal to distal, and we found the enlarge-

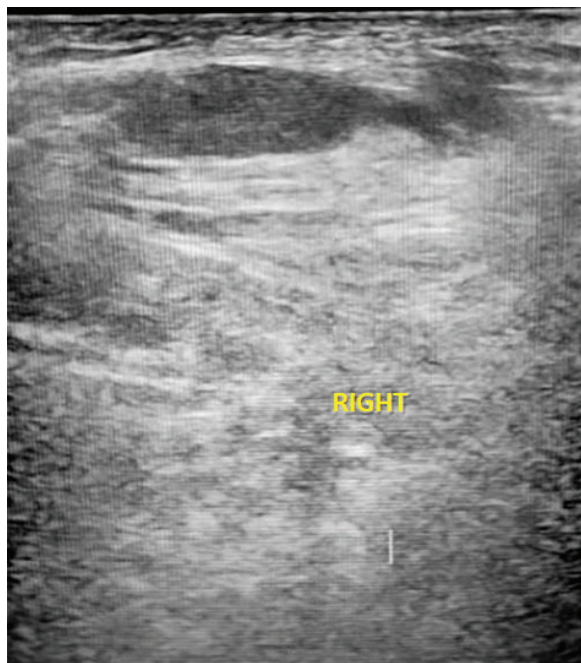


Fig. 2. Preoperative ultrasound showing dense echo in the soft tissue of the right palm.

ment of nerve bundles, the adhesion of the thickening epineurium, and the compression of transverse carpal ligament. We removed most of the hyperplastic fatty lumps, trimmed the epineurium, and performed open carpal tunnel release. After the open carpal tunnel release, the continuity of the median nerve was intact. A Z-shaped incision was made on the ulnar side of the right index finger and the thumb, and the radial side of the ring finger. The intrinsic nerves on the ulnar side of the index finger, and the radial side of the ring finger, had severe fatty infiltration distal to the proximal interphalangeal joint. We excised most of tumors under the microscope, and retained some of the nerve bundle branches and dorsal branches of the index and ring fingers. The postoperative pathological diagnosis was tumor-like hyperplasia of adipose tissue and degeneration and hyperplasia of the fibroblastic tissue of nerves (Fig. 6).

After his second surgery, the patient was hospitalized again in April 2021, due to the recurrence of a mass and pain in the right palm, obvious swelling and numbness of the right index and ring fingers, and limited flexion and extension activities of the right ring finger. Physical examination upon admission suggested that the right middle finger was absent, and the incision of the right palm, the thumb, the index finger, and the ring finger healed well. There was an 8cm x 4cm irregular soft tissue mass on the radial side of the right palm and around the thenar eminence. The right index finger body was obviously swollen, with the deformation of the puffy distal phalanx. Scar contracture appeared on the ulnar side of the right ring finger, and some soft tissue thickening (Fig. 7). Flexion and extension activities were restricted in the right index finger, accompanied by skin numbness. In addition, the peripheral blood flow was normal. Auxiliary examinations, including B-scan ultrasonography, X films and magnetic resonance imaging (MRI), were performed. B-scan ultrasonography revealed thickening of local soft tissues of the right index finger,

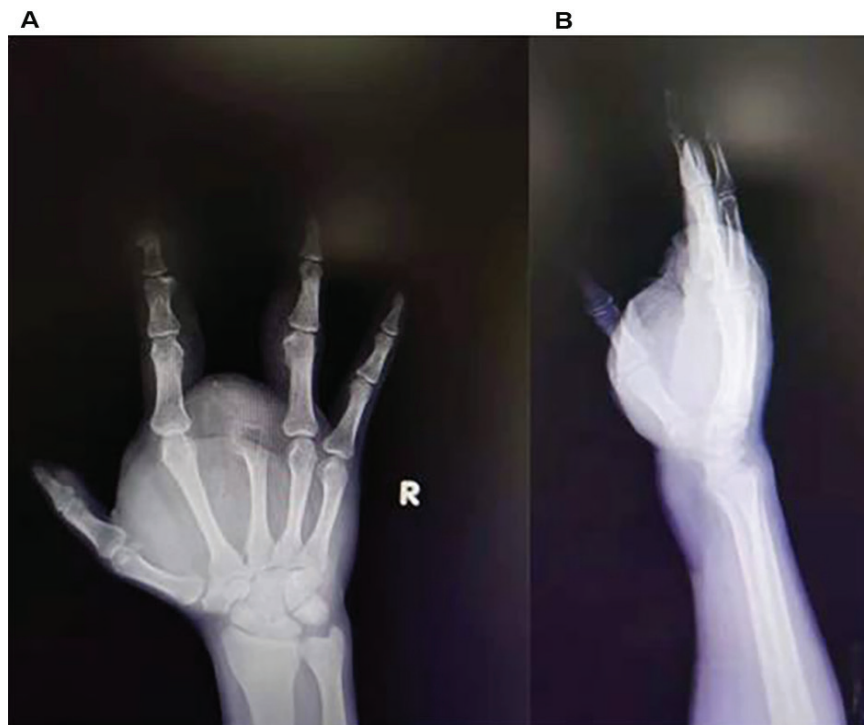

Fig. 3. Preoperative X films of frontal position of the right hand (A) and lateral position of the right hand (B) showing the thickened soft tissue, the absent right middle finger, deformation of the third metacarpal head, and deformation of the articular surface of the middle phalanx of the index finger.

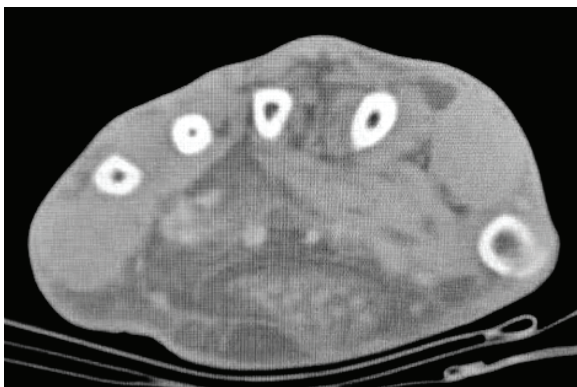


Fig. 4. Preoperative CT axial image of the right hand showing a solid mass in the soft tissue area of the right palm with hypodensity.

right ring finger, and right palm, and multiple strong echogenic and hypoechoic areas (Fig. 8). X films showed the absent right middle finger, enlargement and deformation of the third metacarpus head with reduced bone density, and osteophyte deformation of the proximal phalanx and middle phalanx of the index finger and the proximal phalanx of

the ring finger (Figs. 9A and 9B). MRI showed abnormal signal shadows on the volar side of the right wrist, which suggested tumor recurrence, fat accumulation around the lesion and at the distal of the third metacarpophalangeal joint of the right hand, hypertrophy of the right index figure and ring finger, and the absence of the middle finger (Fig. 10A, 10B, and 10C).

The same S-shaped incision was made on the right palm and the volar side of the right forearm. Intraoperatively, an obvious adipose tissue-occupying lesion was observed, with uneven median nerve fiber bundles, severe fibrosis, and severe fatty and fibrous tissue infiltration (Fig. 11A, 11B, 11C, and 11D). We performed the dissection from the middle of the forearm to the fingers of the right hand to expose the normal range of the median nerve and the recurrent branch of the median nerve, and then we cut the intrinsic nerve at the proximal on the radial and ulnar sides of the thumb. Subse-

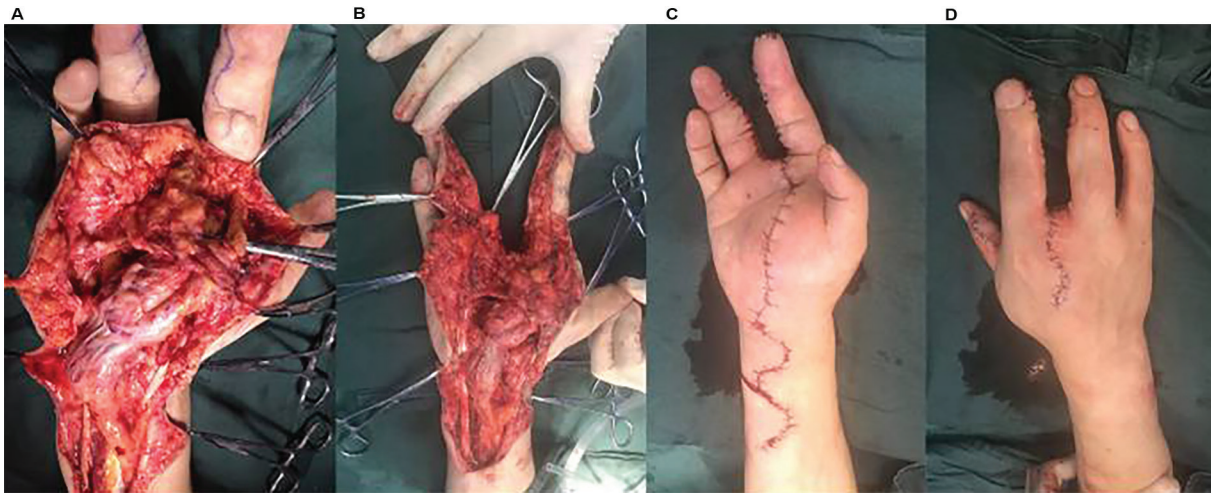


Fig. 5. Intraoperatively, the tumor extensively infiltrated the median nerve of the right wrist, and the digital nerves of the right index and ring finger (A and B); Postoperatively, the incision was sutured and the peripheral blood flow was good after loosening the tourniquet (C and D).

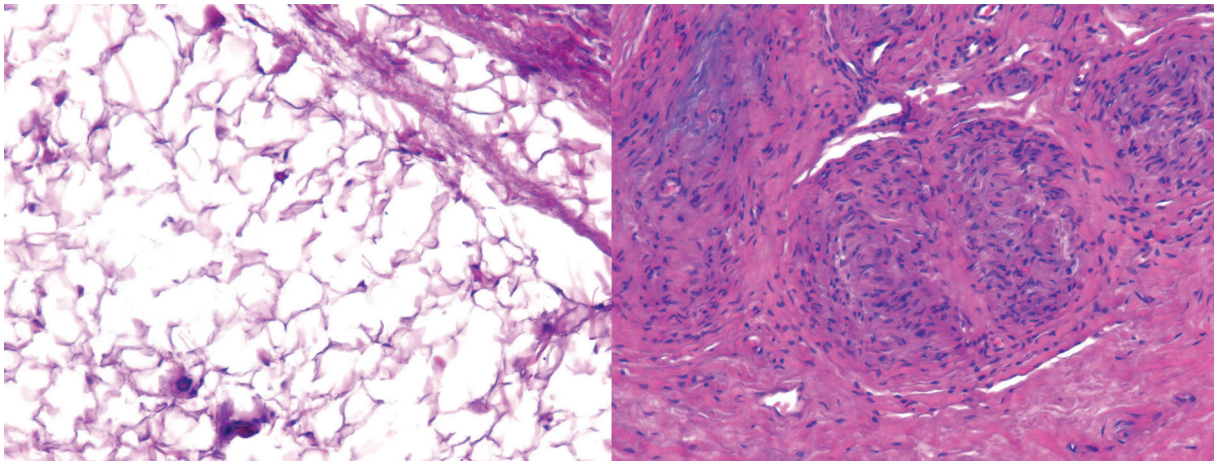


Fig. 6. Postoperative pathology showing tumor-like proliferation of fibrous and adipose tissue and partial degeneration of neural tissue.

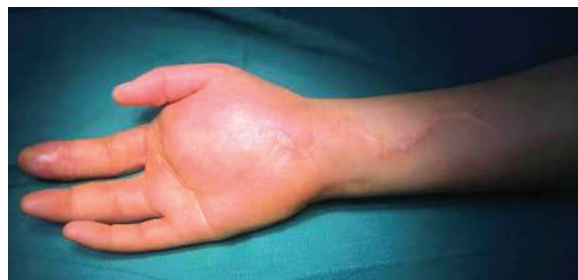

Fig. 7. Preoperative soft tissue tumor of the right palm.

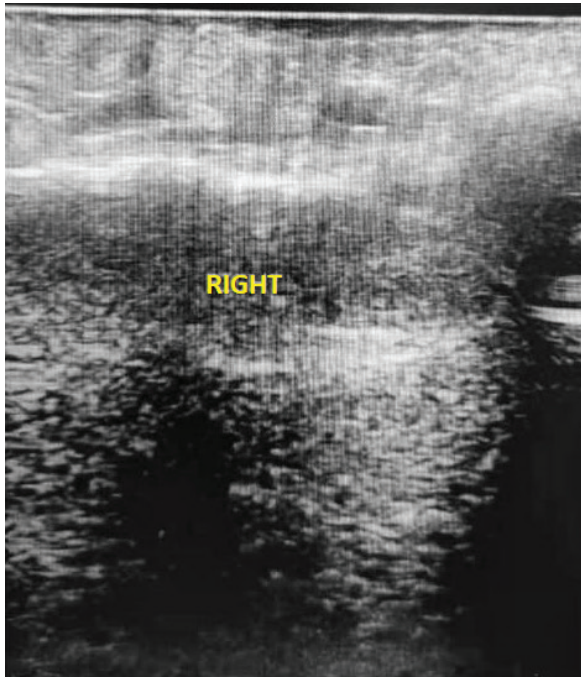


Fig. 8. Preoperative ultrasound showing local soft tissue thickening of the right palm with multiple hyperechoic and hypoechoic areas.

quently, the diseased median nerve and fat mass were completely removed. According to the length of the defective median nerve, the sural nerve of 36 cm was excised from the left calf, and folded into double strands to do the nerve transplantation and repair the defective median nerve. The superficial palmar arch artery had serious adhesion to the tumor tissue, and it ruptured during the separation, and was repaired via microscopic anastomosis. A Z-shape incision was made on the volar side of the right index finger and the radial side of the right ring finger, and then the adipose tissues were removed again for volume reduction. The proper digital artery on the radial side of the index finger at the proximal ruptured, and was repaired via microscopic anastomosis using ramus palmaris superficialis arteriae radialis. Postoperatively, the peripheral blood flow was good. The postoperative pathological diagnosis was tumor-like hyperplasia of fibrous fat and neural tissue (Fig. 12).

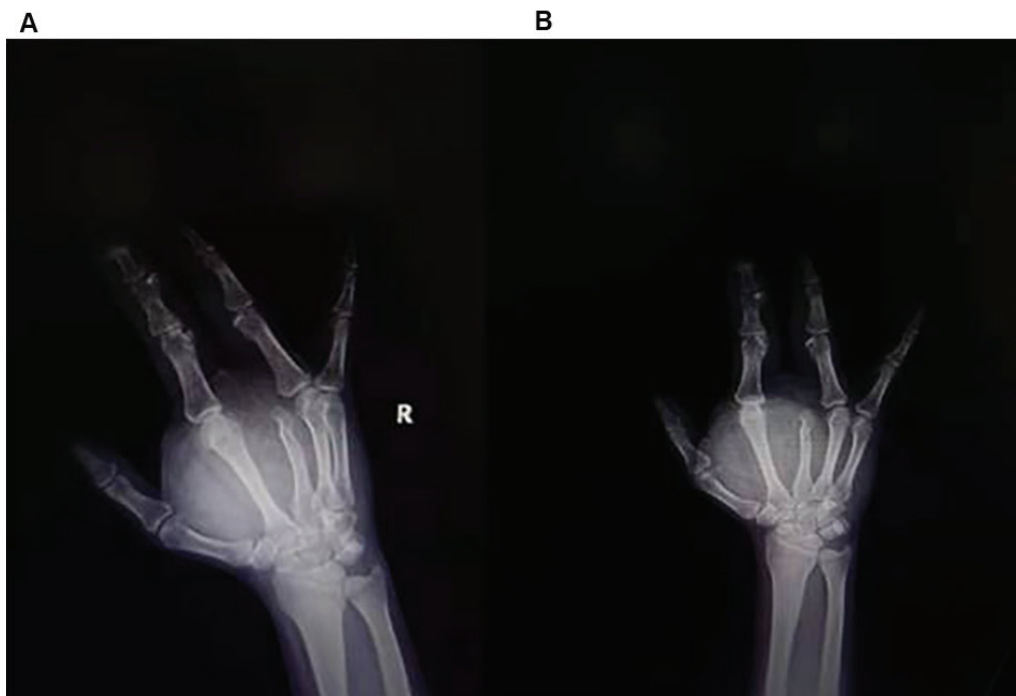

Fig. 9. Preoperative X films of oblique position (A) and frontal position (B) of the right hand showing soft tissue mass thickening of the right palm, and osteophyte deformation of the proximal and middle phalanges of the right index finger and the proximal phalanx of the ring finger.

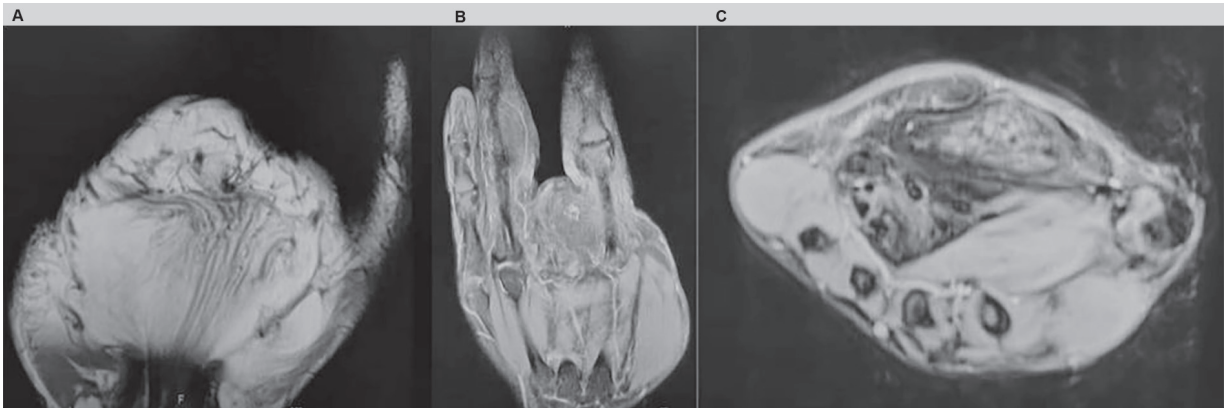


Fig. 10. For preoperative MRI, coronal T1 showing serpiginous structures-like changes (A), coronal T2 showing abnormal signal of the ring finger mass occupancy (B), and axial T2 showing coaxial cable-like appearance (C).

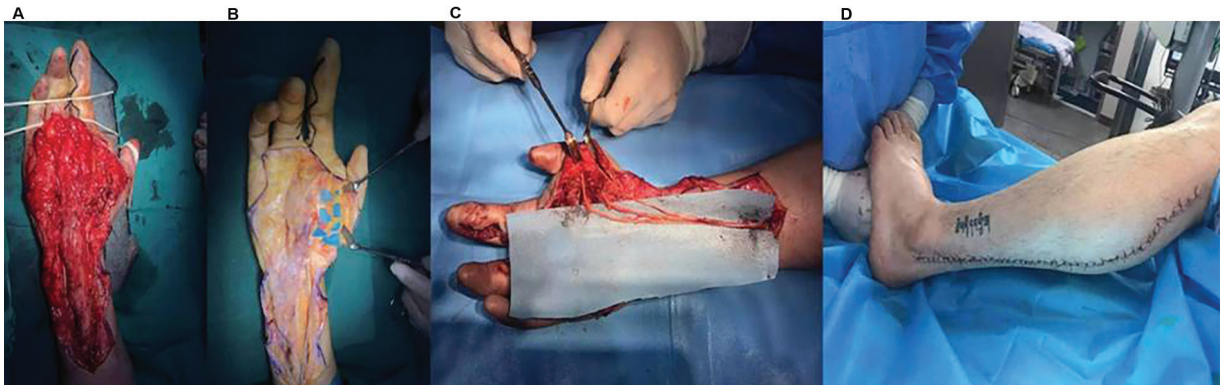


Fig. 11. Intraoperatively, the fatty tissue occupation was obvious, and the thickness of median nerve fiber bundles was uneven, with severe fibrosis as well as fatty and fibrous tissue infiltration (A and B); the median nerve was excised for sural nerve transplantation and repairment (C and D).

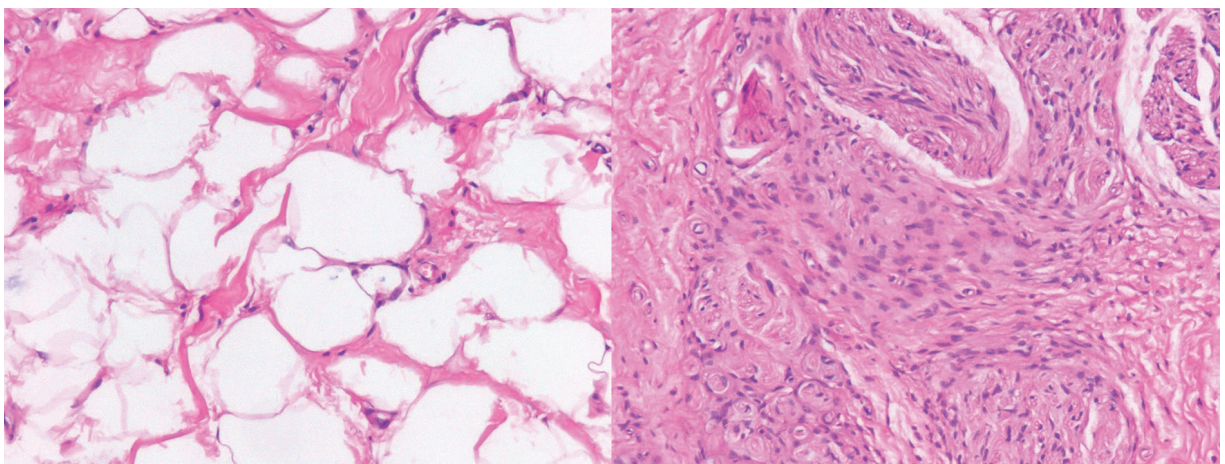


Fig. 12. Postoperative pathology showing tumor-like hyperplasia of fibroadipose tissue and fibrotic degeneration of neural tissue.

DISCUSSION

Definition and naming

FLH is a rare benign tumor, which mainly occurs in the nerves of the upper limbs. It originates from the abnormal growth of the fibroadipose tissue of the nerve sheath, resulting in the fusiform enlargement of the affected nerves^{4,5}. The fibroid degeneration of the compressed nerve bundles is caused by the proliferation of adipose tissues⁶. The median nerve and its branches are involved in 85% of cases. FLH has several synonyms, such as lipofibromatous hamartoma, lipofibroma, fibrofatty proliferation of the nerve, fatty infiltration of the nerve, fibrolipoma of the nerve, intraneural lipofibroma, neural fibrolipoma, and macrodactylia fibrolipomatosis^{5,7}. In the classification of soft tissue tumors by the World Health Organization (WHO) in 2013, fibrolipomatous hamartoma of the nerve, fatty infiltration, and neural fibrolipoma are all classified as lipomatosis of the nerve¹, which is different from intraneural lipoma in the clinical manifestations and treatment⁸. Due to the confusion of naming and the rarity of this disease, its diagnosis and treatment are complicated. The proper terminology for this lesion has been inconsistent in the literature and it is currently recommended that the most accurate term for this lesion is “fibrolipoma”⁹, which best reflects the hamartomatous nature of this lesion. We also prefer the term “fibrolipomatous hamartoma of the nerve”.

Epidemiology

This lesion was firstly reported by Mason in 1953². In 1969, Johnson and Bonfiglio firstly called this lesion as lipofibromatous hamartoma¹⁰. In 1994, Guthikonda *et al.* proposed a new classification for neural lipomatous tumours: (a) soft lipoma, (b) intraneural lipoma, (c) lipofibromatous hamartoma, and (d) macrodystrophia lipomatosa¹¹. FLH commonly occurred in those under 30 years old¹². This lesion in infants, children, and young adults was manifest-

ed by either no symptoms or compressive neuropathy⁴. In many cases, the mass has existed for many years before the onset of symptoms¹³. The incidence of the FLH with macrodactyly in women is twice as much as in men. The incidence of the FLH without macrodactyly in women is the same than in men, and the incidence of the FLH in the upper limbs is higher than that of the lower limbs¹⁴⁻¹⁶. In our reported case, the FLH occurred in a young man, involving unilateral median nerve and its branches, accompanied by macrodactyly.

Etiology and Pathogenesis

Although some potential etiologies have been described, the cause of this abnormal growth of the nerve is still unknown, which is possibly due to the proliferation and hypertrophy of fibroblasts and mature adipocytes in the epineurium¹⁷. A considerable number of cases occur at birth or in childhood. Many scholars believe that it may be a congenital disease caused by the abnormal development of the flexor retinaculum or transverse carpal ligament, especially in the carpal tunnel area or with macrodactyly. There are also cases with an overgrowth of bone tissue and skin soft tissue^{12,18}. Some scholars believe that FLH is acquired and caused by reactions such as trauma or long-term chronic irritation^{4,9}. The true etiology might be the combination of congenital factors and acquired and reactive factors, which stimulate the formation of the tumor¹⁹. Our reported case who had no history of trauma, presented with macrodactyly at birth, and his tumor recurred and continued to proliferate after two surgeries.

Although FLH is hyperproliferative, its behavior resembles that of a benign tumor, with no evidence of malignancy in confirmed cases and no familial cases. The FLH subtype has been reported to be associated with mutations in the PIK3CA pathway²⁰, similar to other hyperproliferative disorders. Neuroregional macrodactyly is a common comorbidity, and 20–66% of FLH cases experienced

this macrodactyly^{14,15,21}. The exact relationship between the two remains elusive.

Clinical Manifestations

Typical FLH cases mainly occur in the first three decades of life, mostly at birth or in early childhood. Locally, gradually enlarging painless masses are the main symptom. 90% of cases are unilateral^{12,22}. The course of the disease is variable, and the affected finger is symmetrically or asymmetrically thickened, which is often accompanied by dyskinesia. This kind of tumor mainly occurs in the upper limb, and the median nerve and its branches are the most commonly affected nerves, especially the median nerves at the distal end of the forearm and on the volar side of the wrist¹². Pain, numbness, sensory abnormalities, and nerve entrapment syndrome usually occur in the late stage of this disease²³. Approximately one-third of cases are accompanied with macrodactyly, which is commonly seen in the phalanges. However, there was a case report describing an elderly patient with macrodactyly in the metacarpal bone¹². The case we reported presented with macrodactyly of the middle finger at birth. Unfortunately, because the clinicians in the local county hospital at that time had a lack of understanding of this disease, they performed the middle finger amputation to relieve pain and numbness of the patient.

Imaging Examinations

(1) B-scan ultrasonography suggests a dense-echo mass in the hypoechoic area. Nerve bundles are in the hypoechoic area, and adipose tissues are in the hyperechoic area. Color Doppler shows no blood flow signal¹⁸.

(2) X-ray films show thickened soft tissues, and examine the bone for hypertrophy, hyperplasia, and other deformities¹⁵.

(3) MRI is the gold standard for the diagnosis of this disease^{24,25}, which is helpful for the differentiation and preoperative evaluation. Fat with high-signal intensity is

showed on T1- and T2-weighted images. In the T1-weighted axial images, there is typical fat with high-signal intensity and nerves with a low-signal intensity and co-axial cable-like appearance. Coronal images showed serpiginous structures, and thickened nerve bundles were wrapped by adipose tissues, separated from each other, and evenly distributed in the nerve sheath. Fat in the T1-weighted images showed high-signal intensity, while fat in the T2-weighted images with fat suppression showed low-signal intensity. Fat was asymmetrically distributed, and sagittal images showed a spaghetti-like appearance. These specific features of MRI can be used as diagnostic criteria, even without a pathological biopsy^{3,14}. For the case we reported, the preoperative MRI showed typical coaxial cable-like appearance and spaghetti-like serpiginous structures, which was very helpful for early diagnosis.

(4) Electromyography and nerve conduction examination are helpful to diagnose nerve compression lesions¹².

Pathological Examination

(1) General observation shows this kind of tumor is irregularly fusiform, its color is yellow or yellowish-brown, and the affected nerves may be elongated, thickened and uneven in thickness, which is caused by the excessive proliferation of mature adipocytes and fibrous tissue^{19,25}.

(2) Histological morphology shows excessive proliferation of the adventitial fibroadipose tissues of the affected nerves and extensive infiltration of the nerve bundles, and the adventitial fibroadipose tissues wraps, separates, and compresses these nerve bundles. In cases with a long course of disease, degenerative and atrophic changes of nerve tissues may occur. Fibrous tissues and perineurial cells located around the nerve bundle are arranged in concentric circles.^{12,26} Unlike lipomas, the FLH presents infiltrative growth and fat is asymmetrically distributed between nerve bundles^{12,26}. In the proliferative fibrous fat

tissue, the hyperplasia of medium and small blood vessels and lymphatics occurs focally, and hemangioma or lymphangioma-like changes may appear in some areas. In addition to the above-mentioned typical morphology, bone metaplasia may also occur in a few cases. Immunohistochemical markers have no special significance for the diagnosis of this disease, with being positive for CD34, S100, and vimentin and negative for epithelial membrane antigens, desmin, and glial fibrillary acidic protein antibodies ²⁶.

Differential diagnosis

Clinically, many lesions need to be differentiated from FLH, such as neurofibroma, neurilemoma, neuroma, ganglion, lipoma, vascular malformation, intraneural neuroectodermal tumor, intraneural lipoma, and traumatic neuroma ^{6,18}.

Treatment

Although FLH is a benign tumor, due to the rarity of this disease and the lack of randomized controlled studies, it is difficult to determine the best treatment for it. So far, the surgical approach of FLH has been controversial.

(1) Conservative treatment is an option for asymptomatic individuals ^{16,27}, for whom there are no neurological symptoms such as pain, numbness or sensory abnormalities, and if the tumor is small enough not to affect the function and aesthetic of the affected limb. There is no evidence of malignancy. It primarily requires observation or a pathological biopsy ⁸.

(2) Carpal tunnel release is recommended to those with symptoms of median nerve compression, including traditional incision release, microscopic or arthroscopic carpal tunnel release, and epineurium incision and intraneural release as appropriate ⁴. Nerve decompression can reduce pain, numbness and the risk of the sequelae of sensorimotor disorders ¹². It can also shrink the mass and improve thumb-to-palm strength ^{16,27}. If there are no characteristic imaging findings,

a surgical exploration and an excisional biopsy are required to clarify the diagnosis.

(3) Microscopic resection is recommended if the tumor is large, and vascular injury and fibrosis further aggravate the nerve damage ^{13,16}. For cases of continuous and progressive deterioration of neurological symptoms, in order to maximize the preservation of nerve function, when the tumor resection was performed, interfascicular tumor dissection was performed together under a microscope. However, the dissection may cause segmental nerve ischemia ^{12,16,28}. Therefore, the specific indications for this technique are still controversial.

(4) Tumor and volume reduction, especially for cases combined with macrodactyly or swollen/deformed fingers, is recommended. In order to improve the appearance of the affected finger while preserving nerve function, tumor reduction surgery can be selected for soft tissue reduction, and if necessary, epiphyseal block, osteotomy correction, or the removal of the affected finger nerve was performed ^{26,28}. For some elderly patients, finger or limb amputation can be considered ²⁶.

(5) The radical resection of the tumor is only performed in the cases of neurodisabling damage. Some scholars believe that this may lead to intolerable sensorimotor defects ^{7,12,28}. If the tumor involves the brachial plexus nerve, it is difficult to completely remove the tumor ¹². Postoperative fibrosis caused by fiber healing can significantly interfere with the nerve conduction ^{15,28}, so that motor and sensory loss in the innervated area may occur. The improvement of motor functions requires tendonoplasty repair, and although nerve grafting is an option for sensory restoration, there is still no satisfactory solution.

For this case we report, when the patient firstly came to our hospital for surgery, a large number of proliferating fibers and fatty tumor tissues surrounding the nerve bundles were observed during operation. It was very challenging to completely

remove the tumor. Therefore, we decided to remove most of the tumor tissue to reduce its size, and loosen the carpal tunnel, while the median nerve and the finger nerves were preserved, which significantly reduced the patient's symptoms and improved the appearance of the affected finger. Three years after this operation, the tumor recurred and the patient was admitted again to our hospital for surgery. Due to extensive adhesion of the tumor tissue and the median neurofibrillary degeneration, the tumor and the median nerve of the diseased segment were removed, and then the sural nerve was cut to do the nerve grafting and repair. After this operation, the symptoms of the patient were relieved, and the feelings and activities of the palms and fingers were restored to the greatest extent.

CONCLUSION

The FLH is clinically rare, and its exact epidemiology and etiology are not well understood. In cases of a painless mass in the wrist, combined with macrodactyly, FLH is highly suspected. Magnetic resonance imaging and pathological examination are helpful to clarify the diagnosis. Although FLH is a benign tumor, the individual treatment plan is the best choice according to the severity of the patient's symptoms. Therefore, clinicians, radiologists, and pathologists need to further explore and understand this disease.

Funding

This research received no specific grant from any funding agency in the public, commercial, or not-for-profit sectors.

Ethics approval and consent to participate

This study was conducted in accordance with the declaration of Helsinki. This study was conducted with approval from the Ethic committee of Honghui Hospital, Xi'an Jiaotong University.

Consent for publication

Written informed consent to publish the clinical details and images of the patient was obtained.

Conflict of interests

All authors declare they have no conflict of interests.

Authors ORCID Numbers

- Y-Ting Dang (YT D):
0000-0001-8486-3839
- Qiang Wang (QW):
0000-0002-4458-4912
- Yun-Ping Zhou (Y-P Z):
0000-0002-7399-1269
- Deng-Ke Wei (D-K W):
0000-0002-4534-6801
- Fei Xie (FX) <https://orcid.org/0000-0002-7984-1093>

Contributions Authors'

YT D, FX, Substantial contributions to the conception and design of the work.

YT D, QW, Y-P Z, D-KW, X-H O, FX, the acquisition, analysis, and interpretation of data for the work.

YT D, drafting the work.

YT D, QW, Y-P Z, D-K W, X-H O, F X, revising it critically for important intellectual content.

YT D, QW, Y-P Z, D-K W, X-H O, F X, final approval of the version to be published and agreement to be accountable for all aspects of the work in ensuring that questions related to the accuracy or integrity of any part of the work are appropriately investigated and resolved.

REFERENCES

1. **Fletcher CD.** The evolving classification of soft tissue tumours—An update based on the new 2013 WHO classification. *Histopathology* 2014; 64: 2–11. doi: 10.1111/his.12267.
2. **Mason ML.** In presentation of cases: Proceedings of the American Society for Surgery of the hand. *J Bone Joint Surg (Am)* 1953; 35A: 273-274.
3. **Kini JR, Kini H, Rau A, Kamath J, Kini A.** Lipofibromatous hamartoma of the median nerve in association with or without macrodactyly. *Turk J Pathol* 2018; 34(1): 87–91.
4. **Hankins CL.** Carpal tunnel syndrome caused by a fibrolipomatous hamartoma of the median nerve treated by endoscopic release of the carpal tunnel. *J Plast Surg Hand Surg* 2012; 46(2):124-7. doi: 10.3109/2000656X.2011.573923.
5. **Nanno M, Sawaizumi T, Takai S.** Case of fibrolipomatous hamartoma of the digital nerve without macrodactyly. *J Nippon Med Sch* 2011; 78(6):388-92. doi: 10.1272/jnms.78.388.
6. **Kitridis D, Dionellis P, Xarchas K, Givissis P.** Giant median nerve due to hamartoma causing severe carpal tunnel syndrome. *J Orthop Case Rep* 2018; 8(4): 57-60. doi: 10.13107/jocr.2250-0685.1160.
7. **Teles AR, Finger G, Schuster MN, Gobatto PL.** Peripheral nerve lipoma: Case report of an intraneural lipoma of the median nerve and literature review. *Asian J Neurosurg* 2016; 11: 458. doi: 10.4103/1793-5482.181118.
8. **Okubo T, Saito T, Mitomi H, Takagi T, Torigoe T, Suehara Y, Katagiri H, Murata H, Takahashi M, Ito I, Yao T, Kaneko K.** Intraneural lipomatous tumor of the median nerve: Three case reports with a review of literature. *Int J Surg Case Rep* 2012; 3(9): 407-411. doi: 10.1016/j.ijscr.2012.05.007.
9. **Nilsson J, Sandberg K, Dahlin LB, Vendel N, Balslev E, Larsen L, Nielsen NS.** Fibrolipomatous hamartoma in the median nerve in the arm - an unusual location but with MR imaging characteristics: a case report. *J Brachial Plex Peripher Nerve Inj* 2010; 5: 1. doi: 10.1186/1749-7221-5-1.
10. **Johnson RJ, Bonfiglio M.** Lipofibromatous hamartoma of the median nerve. *J Bone Joint Surg Am* 1969; 51: 984-990.
11. **Guthikonda M, Rengachary SS, Balko MG, van Loveren H.** Lipofibromatous hamartoma of the median nerve: case report with magnetic resonance imaging correlation. *Neurosurgery* 1994; 35: 127–132. doi: 10.1227/00006123-199407000-00019.
12. **Razzaghi A, Anastakis DJ.** Lipofibromatous hamartoma: review of early diagnosis and treatment. *Can J Surg* 2005; 48(5): 394-9. PMID: 16248139.
13. **Gennaro S, Meriadri P, Secci F.** Intraneural lipoma of the median nerve mimicking carpal tunnel syndrome. *Acta Neurochir (Wien)* 2012; 154: 1299–1301. doi: 10.1007/s00701-012-1303-7.
14. **Muhammad A, Waheed AA, Khan N, Sayani R, Ahmed A.** Fibrolipomatous hamartoma of the median nerve with macrodystrophia lipomatosa. *Cureus* 2018; 10(3): e2293.
15. **Saeed MAM, Dawood AA, Mahmood HM.** Lipofibromatous hamartoma of the median nerve with macrodactyly of middle finger. *J Clin Orthop Trauma* 2019; 10: 1077–1081. doi: 10.1016/j.jcot.2019.05.023.
16. **Robinson AJ, Basheer MH, Herbert K.** An unusual cause of carpal tunnel syndrome. *J Plast Reconstr Aesthet Surg* 2010; 63: e788-791. doi: 10.1016/j.bjps.2010.06.019.
17. **Marek T, Spinner RJ, Syal A, Mahan MA.** Strengthening the association of lipomatosis of nerve and nerve-territory overgrowth: a systematic review. *J Neurosurg* 2019 Mar 29; 132(4): 1286-1294. doi: 10.3171/2018.12.JNS183050.
18. **Senger JL, Classen D, Bruce G, Kanthan R.** Fibrolipomatous hamartoma of the median nerve: a cause of acute bilateral carpal tunnel syndrome in a three-year-old child: a case report and comprehensive literature review. *Plast Surg (Oakv)* 2014; 22: 201–206.
19. **Al-Jabri T, Garg S, Mani GV.** Lipofibromatous hamartoma of the median nerve. *J Orthop Surg Res* 2010 ;5: 71. doi: 10.1186/1749-799X-5-71.
20. **Blackburn PR, Milosevic D, Marek T, Folpe AL, Howe BM, Spinner RJ, Carter JM.** PIK-3CA mutations in lipomatosis of nerve with or without nerve territory overgrowth. *Mod*

- Pathol 2020; 33(3): 420-430. doi: 10.1038/s41379-019-0354-1.
21. **Agrawal R, Garg C, Agarwal A, Kumar P.** Lipofibromatous hamartoma of the digital branches of the median nerve presenting as carpal tunnel syndrome: a rare case report with review of the literature. *Indian J Pathol Microbiol* 2016; 59: 96–98. doi: 10.4103/0377-4929.191752.
 22. **Pallewatte AS, Samarasinghe EC.** Fibrolipomatous hamartoma arising from the median nerve: a case report. *Indian J Radiol Imaging* 2021; 31(2): 472-475. doi: 10.1055/s-0041-1734332.
 23. **Michel CR, Dijanic C, Woernle M, Fernicola J, Grossman J.** Carpal tunnel syndrome secondary to fibrolipomatous hamartoma of the median nerve. *Cureus* 2021; 13(6): e15363. doi: 10.7759/cureus.15363.
 24. **Naveen R.** Fibrolipomatous hamartoma of median nerve: An MRI diagnosis. *Orthop Rheumatol Open Access J* 2016; 3(3): 555614.
 25. **Ranjan R, Kumar R, Jeyaraman M, Kumar S.** Fibrolipomatous hamartoma (FLH) of median nerve: a rare case report and review. *Indian J Orthop* 2021; 55(Suppl 1): 267-272. doi: 10.1007/s43465-020-00149-9.
 26. **Marek T, Mahan MA, Carter JM, Howe BM, Bartos R, Amrami KK, Spinner RJ.** What's known and what's new in adipose lesions of peripheral nerves? *Acta Neurochir (Wien)* 2021; 163(3): 835-842. doi: 10.1007/s00701-020-04620-2.
 27. **Prabhu A, Anil R, Kumar N.** Fibrolipomatous hamartoma of the median nerve: an outcome of surgical management in six consecutive cases. *Niger J Surg* 2020; 26(2): 153-158. doi: 10.4103/njs.NJS_16_20.
 28. **Marek T, Spinner RJ, Syal A, Wahood W, Mahan MA.** Surgical treatment of lipomatosis of nerve: a systematic review. *World Neurosurg* 2019; 128: 587-592.e2. doi: 10.1016/j.wneu.2019.04.110.