

# Neurological manifestations associated with SARS-CoV-2 infection: an updated review.

*Diana Cevallos-Macías<sup>1</sup>, Gilberto Vizcaíno Salazar<sup>1,2</sup> and Aline Siteneski<sup>1,2</sup>*

<sup>1</sup>Facultad de Ciencias de la Salud, Carrera de Medicina, Universidad Técnica de Manabí, Portoviejo, Ecuador.

<sup>2</sup>Instituto de Investigación y Facultad de Ciencias de la Salud, Universidad Técnica de Manabí, Portoviejo, Ecuador.

**Keywords:** Neurological manifestations; neuroinvasive mechanism; COVID-19; SARS-CoV-2.

**Abstract.** SARS-CoV-2 is a single-stranded RNA virus that belongs to the group of seven coronaviruses that affect humans, and its infection causes the COVID-19 disease. The association between the COVID-19 condition and risk factors of neurological manifestations is unclear to date. This review aims to update the main neurological manifestations associated with SARS-CoV-2 disease. First, we present the hypothesis of the neuroinvasion mechanisms of SARS-CoV-2. Then, we discuss the possible symptoms related to patients with COVID-19 infection in the central and peripheral nervous systems, followed by the perspectives of diagnosis and treatment of possible neurological manifestations. The hypothesis of the neuroinvasion mechanism includes direct routes, as the virus crosses the blood-brain barrier or the ACE2 receptor pathway role, and indirect pathways, such as malfunctions of the immune system and vascular system dysregulation. Various studies report COVID-19 consequences, such as neuroanatomic alterations and cognitive impairment, besides peripheral conditions, such as anosmia, ageusia, and Guillain Barré Syndrome. However, the heterogeneity of the studies about neurologic damage in patients after COVID-19 infection precludes any generalization of current findings. Finally, new studies are necessary to understand the adequate diagnosis, therapeutic method of early treatment, and risk group of patients for neurological manifestations of COVID-19 post-infection.

## **Manifestaciones neurológicas asociadas con la infección por SARS-CoV-2: una revisión actualizada.**

*Invest Clin 2023; 64 (1): 108 – 122*

**Palabras clave:** manifestaciones neurológicas; mecanismo neuroinvasivo; COVID-19; SARS-CoV-2.

**Resumen.** El SARS-CoV-2 es un virus de ARN monocatenario que pertenece al grupo de los siete coronavirus que afectan a los humanos y cuya infección causa la enfermedad COVID-19. La asociación entre la infección por COVID-19 y factores de riesgo de manifestaciones neurológicas aún no está clara. Esta revisión tiene como objetivo actualizar la descripción de las principales manifestaciones neurológicas asociadas a la infección por SARS-CoV-2. Presentamos la hipótesis de los mecanismos de neuroinvasión del SARS-CoV-2. Luego discutimos los posibles síntomas asociados a los pacientes con infección por COVID-19 en el sistema nervioso central y periférico y, posteriormente, las perspectivas de diagnóstico y tratamiento de las posibles manifestaciones neurológicas. La hipótesis del mecanismo de neuroinvasión incluye rutas directas cuando el virus cruza la barrera hematoencefálica o tiene acción vía del receptor ACE2 y vías indirectas tales como el mal funcionamiento del sistema inmunitario y la desregulación del sistema vascular. Diversos estudios reportan consecuencias del COVID-19, como la presencia de alteraciones neuroanatómicas y deterioro cognitivo, además de condiciones periféricas como anosmia, agusia y Síndrome de Guillain Barré. La heterogeneidad de los estudios sobre el daño neurológico en pacientes después de la infección por COVID-19 impide cualquier generalización de los hallazgos actuales. Finalmente, son necesarios nuevos estudios enfocándose en comprender el diagnóstico adecuado, el método terapéutico de tratamiento temprano y el grupo de riesgo para las manifestaciones neurológicas de la pos infección por COVID-19.

*Received: 03-09-2022 Accepted: 26-09-2022*

### **INTRODUCTION**

The COVID disease emerged in Wuhan-China in 2019 with rapid transmission and caused severe consequences in society, economies, and healthcare systems <sup>1</sup>. Until July 2022, more than 500 million confirmed cases of COVID-19 and around 6.3 million deaths have been reported worldwide <sup>2</sup>. In this scenario, the data for 2020 showed that the United States had the highest number of cases and deaths from COVID-19 <sup>3</sup>. The agent responsible for these high rates of

morbidity and mortality is SARS-CoV-2. This is a single-stranded RNA virus that belongs to the group of seven coronaviruses that affect humans <sup>4</sup>. The symptomatology associated with COVID-19 is respiratory, mainly fever and cough, and the infection can lead to pneumonia <sup>5</sup>.

The association between COVID-19 infection and risk factors of neurological manifestations is unclear to date. Recent studies report that SARS-CoV-2 causes damage to the central and peripheral nervous systems<sup>6</sup>. Complications such as encephalopathy,

stroke, atypical, neurocognitive disorders, and neuropsychiatric symptom as delirium and confusion are common in severe infections<sup>7</sup>. Post-infection peripheral conditions such as anosmia, ageusia, and Guillain Barré Syndrome have also been previously reported<sup>8</sup>. Apparently, the COVID-19 neurologic manifestation seems familiar and may present as the only symptom without any other manifestation of respiratory system involvement<sup>9</sup>.

Brain analysis of images before and after infection with SARS-CoV-2 suggests that COVID-19 is associated with neuroanatomic alterations and cognitive impairment<sup>10</sup>. In fact, a neuroimaging study with 401 patients with SARS-CoV-2 positive showed structural alterations of the brain, such as longitudinal cortical volume loss and changes in regions<sup>11</sup>. Due to the wide variation of symptoms, individuality, and previous comorbidities in the people, the association between COVID-19 with some neurological manifestations is challenging. In addition, there exists the necessity to evaluate the duration and reversibility of neuroimaging changes observed in studies<sup>10</sup>. Thus, the aim of this review is update of main neurological manifestations associated with SARS-CoV-2 infection. First, we present the hypothesis of the neuroinvasion mechanisms of SARS-CoV-2. Then, we discuss the possible symptoms related to the COVID-19 infection in the central and peripheral nervous systems. Furthermore, we show the perspectives diagnosis of neurological manifestation post-SARS-CoV-2 infection.

### Literature Data Searching

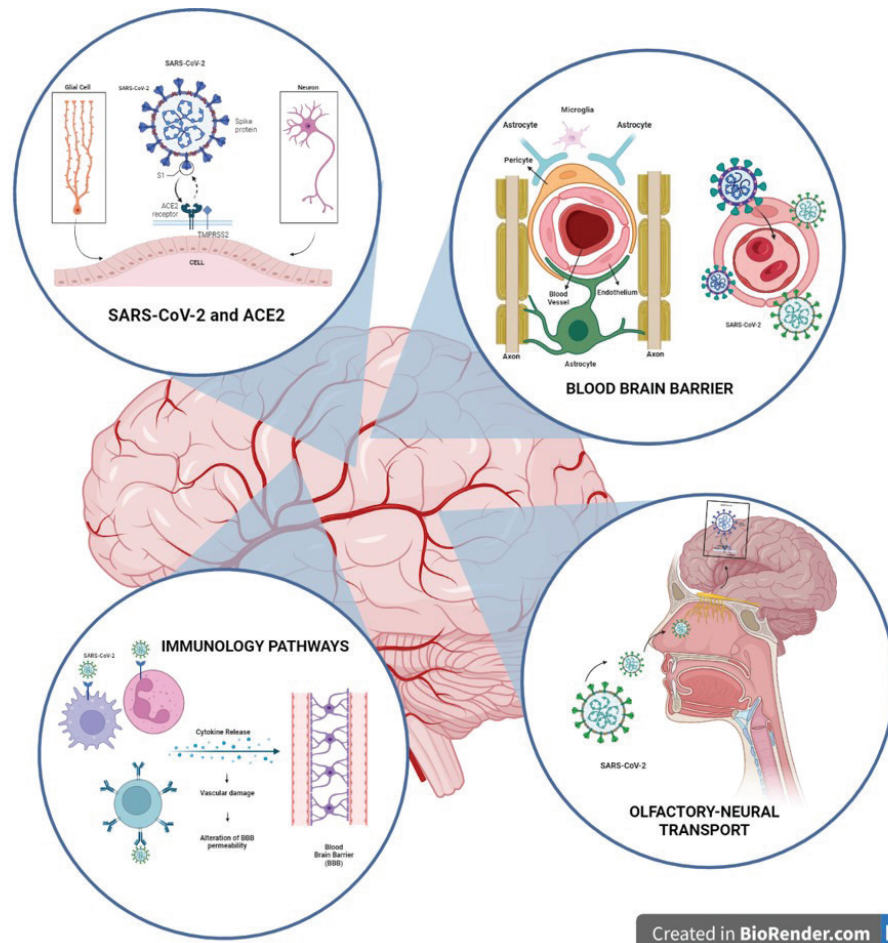
This review presents a mechanistic overview of the clinical research regarding the effects of SARS-CoV-2 on the nervous system. To review possible symptoms associated with the COVID-19 infection in the central and peripheral nervous systems, we selected clinical and epidemiological studies published over two years and two months (May 2020 to July 2022) period. The search

included original manuscripts and contemporary reviews published in English, assessed by specific search terms in the title or abstract of the manuscripts available through PubMed. The search terms used were “SARS-CoV-2 and blood-brain barrier”, “SARS-CoV-2 and neuroinvasion mechanisms”, “SARS-CoV-2 and peripheral nervous system”, and “SARS-CoV-2 and central nervous system”. Additionally, “COVID-19 and blood-brain barrier”, “SARS-CoV-2 and neuroinvasive mechanisms,” “COVID-19 and peripheral nervous system”, and “COVID-19 and central nervous system” We performed a specific screening of the clinical studies that investigated neurobiological manifestations after SARS-CoV-2 in the central and peripheral nervous systems.

### Hypothesis for the neuroinvasion mechanisms of post-infection by SARS-CoV-2

Although the neuroinvasion mechanism of SARS-CoV-2 is uncharted, some hypotheses have been postulated to explain how the virus crosses the blood-brain barrier (BBB)<sup>12</sup> (Fig. 1). The BBB is a multilayer highly effective system that protects the nervous system from an invasion of pathogenic agents and promotes immune responses<sup>13,14</sup>. Some studies postulate that SARS-CoV-2 can infect the endothelial cells, which are cells that compose the BBB and the choroid plexus region that produce the cerebrospinal fluid<sup>15,16</sup>. Through the infection, SARS-CoV-2 accesses the nervous system to the pathway known as the hematogenous pathway<sup>2</sup>, generating a hyperinflammation stage and loss of BBB permeability<sup>17,18</sup>.

The most accepted hypothesis of the neuroinvasion mechanism<sup>2</sup> postulates that the SARS-CoV-2 agent predominantly exploits human protein receptors to the angiotensin-converting enzyme receptor (ACE2 receptor)<sup>19,20</sup>. This receptor expresses on the cell surface of various human cells, including glial cells and neurons. Additionally, to the direct encroach of nerve endings on



Created in BioRender.com bio

Fig. 1. Possible neuroinvasion mechanism post-SARS-CoV-2 infection.

the cell surface, other different transmission routes could facilitate SARS-CoV-2 arrival on the nervous system structures<sup>20</sup>. The olfactory-neural transport may be the route used by SARS-CoV-2 to invade the brain (Fig. 1). A higher expression of ACE2 receptors in neuronal cells exists in the olfactory cells<sup>21,22</sup>. Curiously, in the central nervous system, the ACE2 expression level is significant in pons and medulla oblongata, the neuro-anatomic regions responsible for the brain's respiratory centers<sup>23</sup>. The axon of olfactory neuron cells may form a pathway conducting SARS-CoV-2 to the brain<sup>22</sup>. A study evaluating ACE2 receptor expression in 85 human tissues showed 21 different brain regions<sup>23</sup>

Another hypothesis of the neuroinvasion mechanism of SARS-CoV-2 with indirect

routes includes the immunity pathway with the malfunction of the immune system and dysregulation of the vascular system<sup>13,14,24</sup> (Fig. 1). SARS-CoV-2 may infect the immune cells and produce excessive immune responses that trigger systemic hyperinflammation<sup>25</sup>. In response, the immune cells release cytokines that may damage blood vessels and alter the permeability of the blood-brain barrier<sup>26</sup>. Consequently, infected immune cells are vehicles for disseminating SARS-CoV-2 to the nervous system<sup>27</sup>. The cerebral vascular endothelium has a self-regulatory function in the vascular system. When SARS-CoV-2 invades the vascular endothelium, it can elevate cerebral blood pressure, causing the blood vessel to rupture and reducing the functionality of the vascular system<sup>28,29</sup>.

The classical receptor-mediated endocytosis pathway may allow the SARS-CoV-2 entry into epithelial cells. A recent *in vitro* study explored the hypothesis that SARS-CoV-2 spreads between permissive and nonpermissive neuronal cells<sup>30</sup>. SARS-CoV-2 likely uses tunneling nanotubes membranous conduits rich in actin for intercellular invading nonpermissive cells and potentiating infection in permissive cells. Future studies may explore the permissive and nonpermissive pathways of SARS-CoV-2.

#### **Neurobiological manifestations in the central and peripheral nervous systems post-infection by COVID-19**

In the post-infection by SARS-CoV-2, the patients may present consequences in the central and peripheral nervous systems. However, the relationship between cause and effect of the neurobiological manifestations is still not elucidated entirely<sup>24,29</sup>. Cerebrovascular complications and psychiatry symptoms are reported in the central system and peripheral nervous systems, with demyelinating lesions and neuromuscular symptoms<sup>31,32</sup>. Notably, patients with comorbidities, severe infection, and advanced age are the most vulnerable to neurological manifestation post-infection by SARS-CoV-2<sup>20,29,33-36</sup>.

SARS-CoV-2 causes direct damage to the vascular endothelium and hyperinflammation<sup>37</sup>. Several studies have reported that cerebrovascular disease is a common complication after SARS-CoV-2 infection, with a prevalence oscillating between 2.3%, 1.4%, and 6% of infected patients<sup>37-40</sup>. The common cerebrovascular manifestations are hemorrhagic stroke, ischemic stroke, and the development of coagulopathies such as arterial and venous thrombosis<sup>38,39</sup>. Brain biopsies have shown thrombotic microangiopathies in critically state patients after COVID-19 infection<sup>38</sup>. In addition, hypoxemia and imbalance of the renin-angiotensin system could be involved in the development of cerebrovascular disease manifestation after COVID-19<sup>28</sup>.

Inflammatory lesions of the brain parenchyma, such as encephalitis, have also been documented in patients post-infection with COVID-19<sup>41</sup>. A study showed autopsies with the presence of cerebral edema in patients positive for the infection<sup>42</sup>. The genome sequencing studies have shown the presence of viral antigen of SARS-CoV-2 in cerebrospinal fluid of patients with encephalitis and meningitis. In addition, cases of encephalopathy have been reported in positive COVID-19 patients<sup>43,44</sup>. Seizures have also been a complication in patients hospitalized for COVID-19<sup>45</sup>. Mechanisms such as releasing inflammatory cytokines and stimulating astrocytes and microglia could be involved in seizures<sup>46</sup>. The stimulation induced by the union of SARS-CoV-2 with the ACE2 receptor in neurons releases IL-6, a pro-inflammatory cytokine. Consequently, COVID-19 causes chronic inflammation, and neuronal hyperexcitability can induce epilepsy<sup>47</sup>.

In the context of neurological manifestations, there have been consequences reported in the peripheral nervous system in post-COVID-19 patients<sup>48,49</sup>. Anosmia (loss of smell), ageusia (loss of taste), and hyposmia (decreased smell) are the main manifestations reported in patients post-SARS-CoV-2 infection<sup>31,48</sup>. A study showed that 50% of patients have taste and smell disorders at the onset of COVID-19<sup>49</sup>. Other work exhibits a high prevalence of taste disorders 38.5%, olfactory disorders 35.8%, myalgia 19.3 % 2, and Guillain Barre Syndrome 16.6%<sup>12 50</sup>. The clinical symptoms of ageusia and anosmia could be considered predictors of SARS-CoV-2 infection<sup>51</sup>. A study conducted by Mao *et al.*, with a sample of 214 patients, reports 5.1% with anosmia and 5.6% with ageusia<sup>29</sup>. Possibly, anosmia and ageusia manifestations arise from direct injury to olfactory and taste receptors caused by SARS-CoV-2<sup>52</sup>.

Furthermore, peripherally paresthesias, dyssynergia (loss of motor coordination), areflexia (loss of reflexes), and flaccid paralysis have been observed in some SARS-CoV-2 positive patients<sup>53</sup>. The most frequent mani-

festation is the Guillain Barré Syndrome, characterized by an immune system reaction that attacks peripheral neuron axons. Guillain Barré Syndrome's initial symptoms are peripheral weakness and tingling. The progression of the disease can cause generalized paralysis<sup>54</sup>. The diagnosis may confirm Guillain Barré syndrome in an electroneurography for the absence of the muscle action potential in the axons of peripheral neurons<sup>55</sup>. The first case reported of this syndrome associated with COVID-19 was in Wuhan in a 61-year-old woman<sup>56</sup>.

It is worth highlighting that musculoskeletal symptoms such as myalgias and paresthesias are also manifestations of the peripheral nervous system associated with SARS-CoV-2<sup>12</sup>. An increase in musculoskeletal injury markers such as creatine kinase and lactate dehydrogenase in the blood of some COVID-19 patients was observed<sup>2</sup>. A study conducted in Wuhan showed that 32% of patients presented the clinical symptom of difficulty grasping objects after hospitalization for COVID-19<sup>57</sup>. Indeed, studies suggest that SARS-CoV-2 leads to deficiencies in muscle strength and endurance, possibly due to inflammatory effects<sup>57,58</sup>. A case study reports that post-infection patients correlated the demyelinating lesions with neurologic complications such as anosmia and dysgeusia<sup>31</sup>. On the other hand, despite the negative quarantine experience, it is impossible to establish a cause-and-effect relationship between neuropsychiatric conditions and COVID-19 disease<sup>59</sup>. Individual and environmental factors such as the stress of confinement or a genetic predisposition influenced by stress can contribute to the development of different neuropsychiatric disorders observed in patients post- COVID-19 infection.

#### **Neuroimaging studies with manifestations associated with post-infection by SARS-CoV-2**

Widely used methods of neuroimaging, such as magnetic resonance imaging (MRI) and computed tomography, have

been utilized to diagnose neurobiological manifestations associated with post-infection by SARS-CoV-2<sup>33,60,61</sup>. One study evaluated with MRI 59 patients positive for COVID-19 and diagnosed white matter lesions (39.0%), subacute infarctions (6.8%), leukoencephalopathy (10.2%), and multiple sclerosis (5.1%)<sup>60</sup>. Another study found microhemorrhages related to thrombotic and hypoxic microangiopathy in 3.4% of the patients<sup>61</sup>. Recently, a longitudinal study evaluated 785 participants post-infection by COVID-19 at different times. The research found a reduced tissue contrast and gray matter thickness in the orbitofrontal cortex and parahippocampal gyrus; additionally to changes in functionally connected to the primary olfactory cortex and a reduction in the global brain. Besides, the work data reported a more significant cognitive decline over the evaluation period<sup>11</sup>. Interestingly, the study observed abnormalities in limbic brain regions forming a mainly olfactory network that may indicate a future vulnerability of the limbic system in particular, including memory<sup>11</sup>.

In computed tomography of critical patients with post-infection by COVID-19 intracerebral, intraventricular, and subarachnoid hemorrhage, frontal hypo metabolism, and cerebellar hypermetabolism were observed<sup>28,62</sup>. Curiously, a study evaluating 18 brains of patients who died 0 to 32 days after the onset of symptoms of COVID-19 in the histopathological analysis showed only hypoxic changes and did not show encephalitis or other specific brain changes referable to the infection<sup>63</sup>. A study with post-mortem brain magnetic resonance evaluation of 62 patients dead at a time < 24 hours by COVID-19 demonstrated hemorrhagic and posterior reversible encephalopathy syndrome brain lesions<sup>64</sup>. Additionally, the study showed that the SARS-CoV-2 seems limited to olfactory impairment, and the brainstem evaluation findings do not support a brain-related contribution to the respiratory distress of the patients<sup>64</sup>.

Many studies have focused on searching for biomarkers to express the central nervous system injury induced by SARS-CoV-2<sup>65-68</sup>. Neuronal and astrocyte injury markers, such as the neurofilament light chain protein, showed a sustained increase with maintenance. The glial fibrillary acidic protein showed an early peak in plasma and a decrease in the follow-up of 47 positive patients for COVID-19<sup>66</sup>. More recently, higher serum concentrations of neurofilament light chains were associated with worse clinical outcomes in 142 hospitalized patients positive for COVID-19<sup>67</sup>. The serum concentrations of neurofilament light chains may represent a neuroaxonal injury marker that could predict the extent of neuronal damage<sup>66,67</sup>.

Some studies attempt to correlate the presence of neuroinflammation and vascular injury in patients post-infection by COVID-19. For example, cerebrospinal fluid markers of inflammation, such as neopterin and beta microglobulin, were increased in a study that evaluated six patients<sup>68</sup>. Also, high levels of antiphospholipid antibodies have been shown in positive cases of encephalomyelitis<sup>69</sup>. Finally, studies carried out with PCR report the presence of anti-SARS-CoV-2 antibodies and SARS-CoV-2 RNA in the cerebrospinal fluid<sup>70,71</sup>. Of note is the presence of anti-SARS-CoV-2 and SARS-CoV-2 RNA in the cerebrospinal fluid in patients with severe complications such as encephalitis, meningitis, and demyelinating disease<sup>71</sup>. Currently, it is impossible to affirm the sensitivity of the positive SARS-CoV-2 PCR method in cerebrospinal fluid. In cases of clinical patient examination of the cerebrospinal fluid for viruses such as tick-borne encephalitis, the diagnosis for PCR is not standard because it has low sensitivity. In addition, the presence of the encephalitis virus may be transient in the cerebrospinal fluid. Therefore, it is not yet clear which is the best diagnostic approach to diagnose SARS-CoV-2 CNS infection or the parainfectious immune reaction associated with SARS-CoV-2. So far, there

are no reports on the intrathecal synthesis of SARS-CoV-2-specific IgG<sup>72</sup>.

### Limitations

Our study also has several limitations. First, this review's characteristic and purpose is the literature update. Second, it does not realize a systematic review of post-infection by SARS-CoV-2 to assess the observational and or randomized clinical trials of literature. This paper did not explore the link between SARS-CoV-2 and the neurocognitive deficit. Various factors may influence the correlation of cognitive disorders in people infected by SARS-CoV-2. For example, the stress caused by isolation, the pandemic restrictions, online teaching, and the return to regular activities<sup>73-75</sup>. In addition, different studies report memory loss, cognitive deterioration, depression, and deficits in executive functioning evaluated in different periods after infecting by COVID-19<sup>74,76-78</sup>. Nonetheless, is not possible to differentiate whether the cognitive impairment found in patients post-COVID-19 infection corresponded to mild cognitive impairment or dementia<sup>79</sup>.

### Conclusions and Future Directions

This review discussed the primary evidence underlining the neurobiological manifestations associated with post-infection by SARS-CoV-2. Of particular relevance, compelling evidence suggests that post-infection by SARS-CoV-2 patients presents neurological manifestations in the central and peripheral nervous system. In support, several observational studies have shown cerebrovascular complications and inflammatory lesions in the peripheral system, causing demyelinating lesions and neuromuscular symptoms<sup>31,32,41</sup>. The duration of neurological manifestations after COVID-19 infection seems to vary during the first six months after the illness onset<sup>80</sup>. Given this, some studies have investigated the possible neuroinvasion mechanism of SARS-CoV-2, and postulated hypotheses

to explain the virus penetration across the blood-brain barrier. However, clinical studies assessing the specific manifestations associated with post-infection by SARS-CoV-2 are still scarce, and their results are sometimes controversial.

The discrepant results from observational studies call for the need to conduct future studies. Considering the risk factors and comorbidities in patients, this should be done before affirming the association between neurological manifestations and post-infection by SARS-CoV-2. Neurological complications are associated with the worst mortality rates<sup>81</sup>.

According to a recent systematic analysis, most research published on neurocognitive deficits following SARS-CoV-2 infection recruited subjects before the world's population was utterly immunized<sup>82</sup>. Another systematic review showed that non-specific inflammatory CSF abnormalities were common in patients with post-COVID-19 infection and nervous system syndromes. The study suggests that neurodegeneration biomarkers and a link to neuronal damage with long-term consequences are unknown<sup>83</sup>. On the other hand, in brain MRI, the heterogeneity of the studies about neurologic damage in patients after COVID-19 infection precludes any generalization of the findings<sup>84</sup>. Therefore, new research may assess the potential of post-infection by SARS-CoV-2 to cause neurological manifestations in patients in the current context after worldwide vaccination. In this sense, there are several publications related to SARS-CoV-2 vaccination and neurological disorders such as the thrombotic thrombocytopenic syndrome<sup>85,86</sup>. Finally, the new studies should focus on research to understand the therapeutic method of early treatment, adequate diagnosis, and risk group for neurological manifestations post-infection by SARS-CoV-2<sup>87</sup>.

### Funding

This study was supported by the Instituto de Investigación and Facultad de Ciencias

de la Salud, Universidad Técnica de Manabí, Portoviejo, Ecuador.

### Conflicts of interest

The authors declare that they have no potential conflicts of interest to disclose related to this study.

### Number ORCID of authors

- Diana Cevallos Macías (DCM): 0000-0002-3532-5935
- Aline Siteneski (AS): 0000-0001-6692-7253
- Gilberto Vizcaíno (GV): 0000-0003-2785-1879

### Authorship contribution statement

- DCM: conceptualization; original draft and writing of the manuscript.
- GV: writing and preparing the final draft of the manuscript.
- AS: supervision, writing, and preparing the final draft of the manuscript.
- All authors of this paper have read and approved the final version of the submitted manuscript.

### REFERENCES

1. Guan W, Ni Z, Hu Y, Liang W, Ou C, He J, Liu L, Shan H, Lei C, Hui D, Du B, Li L, Zeng G, Yuen K, Chen R, Tang C, Wang T, Chen P, Xiang J, Li S, Wang J, Liang Z, Peng Y, Wei L, Liu Y, Hu Y, Peng P, Wang J, Liu J, Chen Z, Li G, Zheng Z, Qiu S, Luo J, Ye C, Zhu S, Zhong N. Clinical characteristics of coronavirus disease 2019 in China. *N Engl J Med* 2020; 382(18): 1708-1720. <https://doi.org/10.1056/NEJMoa2002032>.
2. Wan D, Du T, Hong W, Chen L, Que H, Lu S, Peng X. Neurological complications and infection mechanism of SARS-CoV-2. *Signal Transduct Target Ther* 2021; 6(1): 1-11. <https://doi.org/10.1038/s41392-021-00818-7>.



3. Pei S, Yamana TK, Kandula S, Galanti M, Shaman J. Burden and characteristics of COVID-19 in the United States during 2020. *Nature* 2021; 598(7880): 338–341. <https://doi.org/10.1038/s41586-021-03914-4>.
4. Zhu N, Zhang D, Wang W, Li X, Yang B, Song J, Zhao X, Huang B, Shi W, Lu R, Niu P, Zhan F, Ma X, Wang D, Xu W, Wu G, Gao G, Tan W. A novel coronavirus from patients with pneumonia in China, 2019. *N Engl J Med* 2020; 382(8): 727–733. <https://doi.org/10.1056/NEJMoa2001017>.
5. Bhatraju PK, Ghassemieh BJ, Nichols M, Kim R, Jerome KR, Nalla AK, Greninger A, Pipavath S, Wurfel M, Evans L, Kritek P, West T, Luks A, Gerbino A, Dale C, Goldman J, O'Mahony S, Mikacenic C. Covid-19 in critically ill patients in the Seattle Region — case series. *N Engl J Med* 2020; 382(21): 2012–2022. <https://doi.org/10.1056/NEJMoa2004500>.
6. Li H, Xue Q, Xu X. Involvement of the nervous system in SARS-CoV-2 infection. *Neurotox Res* 2020; 38(1): 1–7. <https://doi.org/10.1007/s12640-020-00219-8>.
7. Helms J, Kremer S, Merdji H, Clere-Jehl R, Schenck M, Kummerlen C, Collange O, Boulay C, Fafi-Kremer S, Ohana M, Anheim M, Meziani F. Neurologic features in severe SARS-CoV-2 infection. *N Engl J Med* 2020; 382(23): 2268–2270. <https://doi.org/10.1056/NEJMc2008597>.
8. Valiuddin H, Kalajdzic A, Rosati J, Boehm K, Hill D. Update on neurological manifestations of SARS-CoV-2. *West J Emerg Med* 2020; 21(6): 45–51. <https://doi.org/10.5811/westjem.2020.8.48839>.
9. Favas TT, Dev P, Chaurasia RN, Chakravarty K, Mishra R, Joshi D, Mishra V, Kumar A, Singh V, Pandey M, Pathak A. Neurological manifestations of COVID-19: a systematic review and meta-analysis of proportions. *Neurological Sciences* 2020; 41(12): 3437–3470. <https://doi.org/10.1007/s10072-020-04801-y>.
10. Kremer S, Jäger HR. Brain changes after COVID-19 — how concerned should we be? *Nat Rev Neurol* 2022; 18(6): 321–322. <https://doi.org/10.1038/s41582-022-00661-6>.
11. Douaud G, Lee S, Almagro F, Arthofer C, Wang C, McCarthy P, Lange F, Andersson J, Griffanti L, Duff E, Jbabdi S, Tassler B, Keating P, Winkler A, Collins R, Matthews P, Allen N, Miller K, Nichols T, Smith S. SARS-CoV-2 is associated with changes in brain structure in UK Biobank. *Nature* 2022; 604(7907): 697–707. <https://doi.org/10.1038/s41586-022-04569-5>.
12. DosSantos M, Devalle S, Aran V, Capra D, Roque N, Coelho J, Spohr T, Subilhaça J, Pereira C, D'Andrea M, Niemeyer P, Moura V. Neuromechanisms of SARS-CoV-2: a review. *Front Neuroanat* 2020; 14(37): 1–10. <https://doi.org/10.3389/fnana.2020.00037>.
13. Koyuncu OO, Hogue IB, Enquist LW. Virus infections in the nervous system. *Cell Host & Microbe* 2013; 13(4): 379–393. <https://doi.org/10.1016/j.chom.2013.03.010>.
14. Manglani M, McGavern DB. New advances in CNS immunity against viral infection. *Curr Opin Virol* 2018; 28: 116–126. <https://doi.org/10.1016/j.coviro.2017.12.003>.
15. Yang A, Kern F, Losada P, Ağam M, Maat C, Schmartz G, Fehlmann T, Stein J, Schaum N, Lee D, Calcuttawala K, Vest R, Berdnik D, Lu N, Hahn O, Gate D, Mc Nerney M, Channappa D, Cobos I, Ludwig N, Schulz W, Keller A, Wyss T. Dysregulation of brain and choroid plexus cell types in severe COVID-19. *Nature* 2021; 595(7868): 565–571. <https://doi.org/10.1038/s41586-021-03710-0>.
16. Alquisiras I, Peralta I, Alonso L, Zacapala A, Salmerón E, Aguilera P. Neurological complications associated with the blood-brain barrier damage induced by the inflammatory response during SARS-CoV-2 infection. *Molecular Neurobiology* 2021; 58(2): 520–535. <https://doi.org/10.1007/s12035-020-02134-7>.
17. Pellegrini L, Albecka A, Mallery D, Kellner M, Paul D, Carter A, James L, Lancaster M. SARS-CoV-2 infects the brain choroid plexus and disrupts the blood-CSF barrier in human brain organoids. *Cell Stem Cell* 2020; 27(6): 951–961. <https://doi.org/10.1016/j.stem.2020.10.001>.
18. Wruck W, Adjaye J. SARS-CoV-2 receptor ACE2 is co-expressed with genes related to transmembrane serine proteases, viral entry, immunity and cellular stress.

- Sci Rep 2020; 10(1): 1-12. <https://doi.org/10.1038/s41598-020-78402-2>.
19. Hoffmann M, Kleine H, Schroeder S, Krüger N, Herrler T, Erichsen S, Schiergens T, Herrler G, Wu N, Nitsche A, Müller M, Drosten C, Pöhlmann S. SARS-CoV-2 cell entry depends on ACE2 and TMPRSS2 and is blocked by a clinically proven protease inhibitor. *Cell* 2020; 181(2): 271-280. <https://doi.org/10.1016/j.cell.2020.02.052>.
  20. Han Y, Yuan K, Wang Z, Liu W, Lu Z, Liu L, Shi L, Yan W, Yuan J, Li J, Shi J, Liu Z, Wang G, Kosten T, Bao Y, Lu L. Neuropsychiatric manifestations of COVID-19, potential neurotropic mechanisms, and therapeutic interventions. *Transl Psychiatry* 2021; 11(1): 1-16. <https://doi.org/10.1038/s41398-021-01629-8>.
  21. Bilinska K, Jakubowska P, von Bartheld CS, Butowt R. Expression of the SARS-CoV-2 entry proteins, ACE2 and TMPRSS2, in Cells of the olfactory epithelium: identification of cell types and trends with age. *ACS Chem Neurosci* 2020; 11(11): 1555–1562. <https://doi.org/10.1021/acchemneuro.0c00210>.
  22. Butowt R, Bilinska K. SARS-CoV-2: olfaction, brain Infection, and the urgent need for clinical samples allowing earlier virus detection. *ACS Chem Neurosci* 2020; 11(9): 1200–1203. <https://doi.org/10.1021/acchemneuro.0c00172>.
  23. Lukiw W, Pogue A, Hill J. SARS-CoV-2 infectivity and neurological targets in the brain. *Cell Mol Neurobiol* 2022; 42(1): 217–224. <https://doi.org/10.1007/s10571-020-00947-7>.
  24. Najjar S, Najjar A, Chong D, Pramanik B, Kirsch C, Kuzniecky R, Pacia S, Azhar S. Central nervous system complications associated with SARS-CoV-2 infection: integrative concepts of pathophysiology and case reports. *J Neuroinflammation* 2020; 17(1): 2-14. <https://doi.org/10.1186/s12974-020-01896-0>.
  25. Coperchini F, Chiovato L, Croce L, Magri F, Rotondi M. The cytokine storm in COVID-19: an overview of the involvement of the chemokine/chemokine-receptor system. *Cytokine & Growth Factor Reviews* 2020; 53: 25–32. <https://doi.org/10.1016/j.cytogfr.2020.05.003>.
  26. Mohammadi S, Moosaie F, Aarabi M. Understanding the immunologic characteristics of neurologic manifestations of SARS-CoV-2 and potential immunological mechanisms. *Molecular Neurobiology* 2020; 57(12): 5263–5275. <https://doi.org/10.1007/s12035-020-02094-y>.
  27. Li Z, Liu T, Yang N, Han D, Mi X, Li Y, Liu K, Vuylsteke A, Xiang H, Guo X. Neurological manifestations of patients with COVID-19: potential routes of SARS-CoV-2 neuroinvasion from the periphery to the brain. *Front Med* 2020; 14(5): 533–541. <https://doi.org/10.1007/s11684-020-0786-5>.
  28. Sharifi-Razavi A, Karimi N, Rouhani N. COVID-19 and intracerebral haemorrhage: causative or coincidental? *New Microbes New Infect* 2020; 35: 100669. <https://doi.org/10.1016/j.nmni.2020.100669>.
  29. Mao L, Jin H, Wang M, Hu Y, Chen S, He Q, Chang J, Hong C, Zhou Y, Wang D, Miao X, Li Y, Hu B. Neurologic manifestations of hospitalized patients with coronavirus disease 2019 in Wuhan, China. *JAMA Neurol* 2020; 77(6): 683 – 690. <https://doi.org/10.1001/jamaneurol.2020.1127>.
  30. Pepe A, Pietropaoli S, Vos M, Barba-Spaeth G, Zurzolo C. Tunneling nanotubes provide a route for SARS-CoV-2 spreading. *Sci Adv* 2022; 8(29): eabo0171. [doi:10.1126/sciadv.abo0171](https://doi.org/10.1126/sciadv.abo0171)
  31. Zanin L, Saraceno G, Panciani P, Renisi G, Signorini L, Migliorati K, Fontanella M. SARS-CoV-2 can induce brain and spine demyelinating lesions. *Acta Neurochir* 2020; 162(7): 1491-1494. <https://doi.org/10.1007/s00701-020-04374-x>.
  32. Rogers J, Chesney E, Oliver D, Pollak T, McGuire P, Fusar P, Zandi M, Lewis G, David A. Psychiatric and neuropsychiatric presentations associated with severe coronavirus infections: a systematic review and meta-analysis with comparison to the COVID-19 pandemic. *Lancet Psychiatry* 2020; 7(7): 611–627. [https://doi.org/10.1016/S2215-0366\(20\)30203-0](https://doi.org/10.1016/S2215-0366(20)30203-0).
  33. Xiong W, Mu J, Guo J, Lu L, Liu D, Luo J, Yang D, Gao H, Zhang Y, Lin M, Shen S, Zhang H, Chen L, Wang G, Luo F, Li W, Chen S, He L, Sander J, Zhou D. New onset neurologic events in people with COVID-19 in 3 regions in China. *Neurolo-*

- gy 2020; 95(11): 1479-1487. <https://doi.org/10.1212/WNL.00000000000010034>.
34. Mahammedi A, Saba L, Vağal A, Leali M, Rossi A, Gaskill M, Sengupta S, Zhang B, Carriero A, Bachir S, Crivelli P, Pasché A, Premi E, Padovani A, Gasparotti R. Imaging of neurologic disease in hospitalized patients with COVID-19: an italian multi-center retrospective observational study. *Radiology* 2020; 297(2): 270-273. <https://doi.org/10.1148/radiol.2020201933>.
  35. Romero C, Díaz I, Fernández E, Sánchez A, Layos A, García J, González E, Redondo I, Perona A, DelValle J, Gracia J, Rojas B, Ferial I, Monteagudo M, Palao M, Palazón E, Alcahut C, Sopelana G, Moreno Y, Ahmad J, Segura T. Neurologic manifestations in hospitalized patients with COVID-19. *Neurology* 2020; 95(8): 1060-1070. <https://doi.org/10.1212/WNL.00000000000009937>.
  36. Chua TH, Xu Z, King N. Neurological manifestations in COVID-19: a systematic review and meta-analysis. *Brain Injury* 2020; 34(12): 1549-1568. <https://doi.org/10.1080/02699052.2020.1831606>.
  37. Li Y, Li M, Wang M, Zhou Y, Chang J, Xian Y, Wang D, Mao L, Jin H, Hu B. Acute cerebrovascular disease following COVID-19: a single center, retrospective, observational study. *Stroke Vasc Neurol* 2020; 5(3): 279-284. <https://doi.org/10.1136/svn-2020-000431>.
  38. Tang N, Li D, Wang X, Sun Z. Abnormal coagulation parameters are associated with poor prognosis in patients with novel coronavirus pneumonia. *J Thromb Haemost* 2020; 18(4): 844-847. <https://doi.org/10.1111/jth.14768>.
  39. Hernández F, Sandoval H, Barbella R, Collado R, Ayo O, Barrena C, Molina J, García J, Lozano E, Alcahut C, Martínez A, Sánchez A, Segura T. Cerebrovascular disease in patients with COVID-19: neuroimaging, histological and clinical description. *Brain* 2020; 143(10): 3089-3103. <https://doi.org/10.1093/brain/awaa239>.
  40. Harapan B, Yoo H. Neurological symptoms, manifestations, and complications associated with severe acute respiratory syndrome coronavirus 2 (SARS-CoV-2) and coronavirus disease 19 (COVID-19). *J Neurol* 2021; 268(9): 3059-3071. <https://doi.org/10.1007/s00415-021-10406-y>.
  41. Moriguchi T, Harii N, Goto J, Harada D, Sugawara H, Takamino J, Ueno M, Sakata H, Kondo K, Myose N, Nakao A, Takeda M, Haro H, Inoue O, Suzuki K, Kubokawa K, Ogihara S, Sasaki T, Kinouchi H, Kojin H, Ito M, Onichi H, Shimizu T, Sasaki Y, Enomoto N, Ishihara H, Furuya S, Yamamoto T, Shimada S. A first case of meningitis/encephalitis associated with SARS-Coronavirus-2. *Int J Infect Dis* 2020; 94: 55-58. <https://10.1016/j.ijid.2020.03.062>.
  42. Rimmelink M, Mendonça R, D'Haene N, Clercq S, Verocq C, Lebrun L, Lavis P, Racu M, Trépant A, Maris C, Rorive S, Goffard J, DeWitte O, Peluso L, Vincent J, Decaestecker C, Taccone F, Salmon I. Unspecific post-mortem findings despite multiorgan viral spread in COVID-19 patients. *Critical Care* 2020; 24(1): 495. <https://doi.org/10.1186/s13054-020-03218-5>.
  43. Nath A, Smith B. Neurological complications of COVID-19: from bridesmaid to bride. *Arq Neuropsiquiatr* 2020; 78(8): 459-460. <https://doi.org/10.1590/0004-282x20200121>.
  44. Kholin A, Zavadenko N, Nesterovskiy Y, Kholina E, Zavadenko A, Khondkaryan G. Features of neurological manifestations of the COVID-19 in children and adults. *Zhurnal nevrologii i psikiatrii imeni SS Korsakova* 2020; 120(9): 114. <https://doi.org/10.17116/jnevro2020120091114>.
  45. Parihar J, Tripathi M, Dhamija R. Seizures and epilepsy in times of coronavirus disease 2019 pandemic. *J Epilepsy Res* 2020; 10(1): 3-7. <https://doi.org/10.14581/jer.20002>.
  46. Nikbakht F, Mohammadkhanizadeh A, Mohammadi E. How does the COVID-19 cause seizure and epilepsy in patients? The potential mechanisms. *Mult Scler Relat Disord* 2020; 46: 1-4. <https://doi.org/10.1016/j.msard.2020.102535>.
  47. Tufan A, Avanoglu A, Matucci M. COVID-19, immune system response, hyperinflammation and repurposing antirheumatic drugs. *Turk J Med Sci* 2020; 50(SI-1): 620-632. <https://doi.org/10.3906/sag-2004-168>.
  48. Padda I, Khehra N, Jaferi U, Parmar M. The neurological complexities and prognosis of COVID-19. *SN Compr Clin Med* 2020; 2(11): 2025-2036. <https://doi.org/10.1007/s42399-020-00527-2>.

49. Cherry G, Rocke J, Chu M, Liu J, Lechner M, Lund V, Kumar B. Loss of smell and taste: a new marker of COVID-19? Tracking reduced sense of smell during the coronavirus pandemic using search trends. *Expert Rev Anti Infect Ther* 2020; 18(11): 1165–1170. <https://doi.org/10.1080/14787210.2020.1792289>.
50. López J, Pérez E, León E, Bazán L, Galnares J, Saráchağa A, Briseño M, May R, Vargas E. Síndrome de Guillain-Barré durante la pandemia de COVID-19: experiencia de un centro de referencia en México. *Rev Neurol* 2021; 73(09): 315. <https://doi.org/10.33588/rn.7309.2021364>.
51. Roland L, Gurrola J, Loftus P, Cheung S, Chang J. Smell and taste symptom-based predictive model for COVID-19 diagnosis. *Int Forum Allergy Rhinol* 2020; 10(7): 832–838. <https://doi.org/10.1002/alr.22602>.
52. Vaira L, Salzano G, Deiana G, de Riu G. Anosmia and ageusia: common findings in COVID-19 patients. *Laryngoscope* 2020; 130(7): 1787. <https://doi.org/10.1002/lary.28692>.
53. Toscano G, Palmerini F, Ravaglia S, Ruiz L, Invernizzi P, Cuzzoni M, Franciotta D, Baldanti F, Daturi R, Postorino P, Cavallini A, Micieli G. Guillain-Barré syndrome associated with SARS-CoV-2. *N Engl J Med* 2020; 382(26): 2574–2576. <https://doi.org/10.1056/NEJMc2009191>.
54. Sheikh A, Chourasia P, Javed N, Chourasia M, Suriya S, Upadhyay S, Ijaz F, Pal S, Moghimi N, Shekhar R. Association of Guillain-Barre syndrome with COVID-19 infection: an updated systematic review. *J Neuroimmunol* 2021; 355: 2-7. <https://doi.org/10.1016/j.jneuroim.2021.577577>.
55. Alberti P, Beretta S, Piatti M, Karantzoulis A, Piatti ML, Santoro P, Vigano M, Giovannelli G, Pirro F, Montisano D, Appollonio I, Ferrarese C. Guillain-Barré syndrome related to COVID-19 infection. *Neurol Neuroimmunol Neuroinflamm* 2020;7(4): 741. <https://doi.org/10.1212/NXI.0000000000000741>.
56. Zhao H, Shen D, Zhou H, Liu J, Chen S. Guillain-Barré syndrome associated with SARS-CoV-2 infection: causality or coincidence? *Lancet Neurol* 2020 May;19(5):383–384. [https://doi.org/10.1016/S1474-4422\(20\)30109-5](https://doi.org/10.1016/S1474-4422(20)30109-5).
57. Disser N, de Micheli A, Schonk M, Konnaris M, Piacentini A, Edon D, Toresdahl B, Casey E, Mendias C. Musculoskeletal consequences of COVID-19. *J Bone Joint Surg* 2020; 102(14): 1197–1204. <https://doi.org/10.2106/JBJS.20.00847>.
58. Zhang X, Cai H, Hu J, Lian J, Gu J, Zhang S, Ye C, Lu Y, Jin C, Yu G, Jia H, Zhang Y, Sheng J, Li L, Yang Y. Epidemiological, clinical characteristics of cases of SARS-CoV-2 infection with abnormal imaging findings. *Int J Infect Dis* 2020; 94: 81–87. <https://doi.org/10.1016/j.ijid.2020.03.040>.
59. Brooks S, Webster R, Smith L, Woodland L, Wessely S, Greenberg N, Rubin G. The psychological impact of quarantine and how to reduce it: rapid review of the evidence. *Lancet* 2020; 395(10227): 912–920. [https://doi.org/10.1016/S0140-6736\(20\)30460-8](https://doi.org/10.1016/S0140-6736(20)30460-8).
60. Freeman C, Masur J, Hassankhani A, Wolf R, Levine J, Mohan S. Coronavirus disease (COVID-19) related disseminated leukoencephalopathy: a retrospective study of findings on brain MRI. *AJR Am J Roentgenol* 2021; 216(4): 1046–1047. <https://doi.org/10.2214/AJR.20.24364>.
61. Kremer S, Lersy F, Sèze J, Ferré J, Maa-mar A, Carsin B, Collage O, Bonneville F, Adam G, Martin G, Rafiq M, Geeraerts T, Delamarre L, Grand S, Krainik A, Kremer S, Adam G, Alleg M, Anheim M, Anxionnat R, Ardellier F, Baloglu S, Bapst B, Benzakoun J, Berge J, Bolognini F, Bonneville F, Bornet G, Boulay C, Boulouis G, Boutet C, Brisset J, Caillard S, Carré S, Carsin B, Collange O, Comby P, Constans J, David J, Beaurepaire I, Séze J, Delamarre L, Desal H, Edjlali M, Fabre X, Fafi S, Ferré J, Feuerstein P, Henry M, Forestier G, Gaudemer A, Geeraerts T, Grand S, Hansmann Y, Heintz A, Helms J, Hemmert C, Hmeydia G, Jäger L, Kazémi A, Kerleroux B, Khalil A, Krainik A, Lacalm A, Lecler A, Lecocq C, Lefévre N, Lersy F, Maamar A, Martin G, Matthieu M, Megdiche I, Mertes P, Messié J, Metanbou S, Meyer N, Meziani F, Mutschler V, Nesser P, Oesterlé H, Ohana M, Oppenheim C, Pyatigorskaya N, Rafiq M, Ricolfi F, Saleme S, Schenck M, Schmitt E, Scheneider F, Sebağ N, Talla Y, Thouant P, Willaume T, Zhu F, Zorn

- P, Cotton F. Brain MRI findings in severe COVID-19: a retrospective observational study. *Radiology* 2020; 297(2): 242–251. <https://10.1148/radiol.2020202222>.
62. Delorme C, Paccoud O, Kas A, Hesters A, Bombois S, Shambrook P, Bouillet A, Doukhi D, Le Guennec L, Godefroy N, Maatoug R, Fossati P, Millet B, Navarro V, Bruneteau G, Demeret S, Pourcher V, Delorme C, Corvol J, Delattre J, Carvalho S, Sagnes S, Dubois B, Navarro V, Louapre C, Stojkovic T, Idbaih A, Rosso C, Gales A, Millet B, Rohaut B, Bayen E, Dupont S, Bruneteau G, Lehericy S, Seilhean D, Durr A, Lamari F, Houot M, Brochard V, Dupont S, Lubetzki C, Seilhean D, Pradat P, Rosso C, Hoang K, Fontaine B, Naccache L, Fossati P, Arnulf I, Durr A, Carpentier A, Edel Y, Robain G, Thoumie P, Degos B, Sharshar T, Alamowitch S, Apartis E, Peretti C, Ursu R, Dzierzynski N, Bourron K, Belmin J, Oquendo B, Pautas E, Verny M, Delorme C, Corvol J, Delattre J, Samson Y, Leder S, Léger A, Deltour S, Baronnet F, Gales A, Bombois S, Touat M, Idbaih A, Sanson M, Sanson M, Dehais C, Houillier C, Laigle D, Psimaras D, Alenton A, Younan A, Villain N, Gracli D, Amador M, Bruneteau G, Louapre C, Mariani L, Mezouar N, Mangone G, Meneret A, Hartmann A, Tarrano C, Bendetowicz D, Pradat P, Baulac M, Sambin S, Pichit P, Chochon F, Hesters A, Nguyen B, Procher V, Demoule A, Morawiec E, Mayaux J, Faure M, Ewencyk C, Coarelli G, Heinzmann A, Stojkovic T, Masingue M, Bassez G, Navarro V, An I, Worbe Y, Lambrecq V, Debs R, Musat E, Lenglet T, Lambrecq V, Hanin A, Chougar L, Shor N, Pyatiforskaya N, Galanaud D, Leclercq D, Demeret S, Rohaut B, Cao A, Marois C, Weiss N, Gassama S, Guennec L, Degos V, Jacquens A, Similowski T, Morelot C, Rotgé J, Saudreau B, Millet B, Pitron V, Sarni N, Girault N, Maatoug R, Gales A, Leu S, Bayen E, Thivard L, Mokhtari K, Plu I, Goncalves B, Bottin L, Yger M, Ouvrard G, Haddad R, Ketz F, Lafuente C, Oasi C, Megabarne B, Herve D, Salman H, Rametti A, Chalacon A, Herve A, Royer H, Beauzor F, Maheo V, Lagantot C, Minelli C, Fekete A, Grine A, Biet M, Hilab R, Besnard A, Bouguerra M, Goudard G, Houairi S, Al-Youssef S, Pires C, Oukhedouma A, Siuda K, Malkinson T, Agguini H, Said S, Houot M. COVID-19- related encephalopathy: a case series with brain FDG-positron- emission tomography/computed tomography findings. *Eur J Neurol* 2020; 27(12): 2651–2657. <https://doi.org/10.1111/ene.14478>.
  63. Solomon I, Normandin E, Bhattacharyya S, Mukerji SS, Keller K, Ali A, Adams G, Hornick J, Padera R, Sabeti P. Neuropathological features of Covid-19. *N Engl J Med* 2020; 383(10): 989–992. <https://doi.org/10.1056/NEJMc2019373>.
  64. Coolen T, Lolli V, Sadeghi N, Rovai A, Trotta N, Taccone F, Creteur J, Henrard S, Goffard J, Dewitte O, Naeije G, Goldman S, Tiége X. Early post-mortem brain MRI findings in COVID-19 non-survivors. *Neurology* 2020; 95(14): 2016–2027. <https://doi.org/10.1212/WNL.0000000000010116>.
  65. Ameres M, Brandstetter S, Toncheva A, Kabesch M, Leppert D, Kuhle J, Wellmann S. Association of neuronal injury blood marker neurofilament light chain with mild-to-moderate COVID-19. *J Neurol* 2020; 267(12): 3476–3478. <https://doi.org/10.1007/s00415-020-10050-y>.
  66. Kanberg N, Ashton N, Andersson L, Yilmaz A, Lindh M, Nilsson S, Price R, Blennow K, Zetterberg H, Gisslén M. Neurochemical evidence of astrocytic and neuronal injury commonly found in COVID-19. *Neurology* 2020; 95(12): 1754–1759. <https://doi.org/10.1212/WNL.0000000000010111>.
  67. Prudencio M, Erben Y, Marquez C, Jansen K, Franco C, Heckman M, White L, Dunmore J, Cook C, Lilley M, Song Y, Harlow C, Oskarsson B, Nicholson K, Wszolek Z, Hickson L, O'Horo J, Hoyne J, Gendron T, Meschia J, Petrucelli L. Serum neurofilament light protein correlates with unfavorable clinical outcomes in hospitalized patients with COVID-19. *Sci Transl Med* 2021; 13(602): 1-10. <https://doi.org/10.1126/scitranslmed.abi7643>.
  68. Edén A, Kanberg N, Gostner J, Fuchs D, Hagberg L, Andersson L, Lindh M, Price R, Zetterberg H, Gisslén M. CSF biomarkers in patients with COVID-19 and neurological symptoms. *Neurology* 2020; 96(2): 294-300. <https://doi.org/10.1212/WNL.0000000000010977>.
  69. Benjamin L, Paterson R, Moll R, Pericleous C, Brown R, Mehta P, Athauda D, Ziff O,

- Heaney J, Checkley A, Houlihan C, Chou M, Heslegrave A, Foulkes A, Mummery C, Lunn M, Keddie S, Spyer M, Mckinnon T, Hart M, Carletti F, Jäger H, Manji H, Zandi M, Werring D, Nastouli E, Simister R, Solomon T, Zetterberg H, Schott J, Cohen H, Efthymiou M. Antiphospholipid antibodies and neurological manifestations in acute COVID-19: a single-centre cross-sectional study. *EClinicalMedicine* 2021; 39: 2589-5370. <https://doi.org/10.1016/j.eclinm.2021.101070>.
70. Alexopoulos H, Magira E, Bitzogli K, Kafasi N, Vlachoyiannopoulos P, Tzioufas A, Kotanidou A, Dalakas M. Anti-SARS-CoV-2 antibodies in the CSF, blood-brain barrier dysfunction, and neurological outcome. *Neurol Neuroimmunol Neuroinflamm* 2020; 7(6): 893. <https://doi.org/10.1212/NXI.0000000000000893>.
71. Domingues R, Mendes M, Moura L, Sabino E, Salarini D, Claro I, Santos D, Jesus J, Ferreira N, Romano C, Soares C. First case of SARS-COV-2 sequencing in cerebrospinal fluid of a patient with suspected demyelinating disease. *J Neurol* 2020; 267(11): 3154-3156. <https://doi.org/10.1007/s00415-020-09996-z>.
72. Romoli M, Jelcic I, Bernard R, García D, Mancinelli L, Akhvlediani T, Monaco S, Taba P, Sellner J. A systematic review of neurological manifestations of SARS-CoV-2 infection: the devil is hidden in the details. *Eur J Neurol* 2020; 27(9): 1712-1726. <https://doi.org/10.1111/ene.14382>.
73. Zhou H, Lu S, Chen J, Wei N, Wang D, Lyu H, Shi C, Hu S. The landscape of cognitive function in recovered COVID-19 patients. *J Psychiatr Res* 2020; 129: 98-102. <https://doi.org/10.1016/j.jpsychires.2020.06.022>.
74. Lamontagne S, Winters M, Pizzagalli D, Olmstead M. Post-acute sequelae of COVID-19: evidence of mood & amp; cognitive impairment. *Brain Behav Immun Health* 2021; 17: 1-11. <https://doi.org/10.1016/j.bbih.2021.100347>.
75. Miskowiak K, Johnsen S, Sattler S, Nielsen S, Kunalan K, Rungby J, Lapperre T, Porsberg C. Cognitive impairments four months after COVID-19 hospital discharge: pattern, severity and association with illness variables. *Eur Neuropsychopharmacol* 2021; 46: 39-48. <https://doi.org/10.1016/j.euroneuro.2021.03.019>.
76. Becker J, Lin J, Doernberg M, Stone K, Navis A, Festa J, Wisnivesky J. Assessment of cognitive function in patients after COVID-19 infection. *JAMA Netw Open* 2021; 4(10): 1-4. <https://doi.org/10.1001/jamanetworkopen.2021.30645>.
77. Davis H, Assaf G, McCorkell L, Wei H, Low RJ, Re'em Y, Redfield S, Austin J, Akrami A. Characterizing long COVID in an international cohort: 7 months of symptoms and their impact. *EClinicalMedicine* 2021; 38: 1-19. <https://doi.org/10.1016/j.eclinm.2021.101019>.
78. Alemanno F, Houdayer E, Parma A, Spina A, Forno A, Scatolini A, Angelone S, Bruggiera L, Tettamanti A, Beretta L, Iannaccone S. COVID-19 cognitive deficits after respiratory assistance in the subacute phase: A COVID-rehabilitation unit experience. *PLoS One* 2021; 16(2): 0246590. <https://doi.org/10.1371/journal.pone.0246590>.
79. Tavares J, Souza A, Borges J, Oliveira D, Siqueira J, Sobreira M, Braga P. COVID-19 associated cognitive impairment: a systematic review. *Cortex* 2022; 152: 77-97. <https://doi.org/10.1016/j.cortex.2022.04.006>.
80. Pinzon R, Wijaya V, Jody A, Nunsio P, Buana R. Persistent neurological manifestations in long COVID-19 syndrome: a systematic review and meta-analysis. *J Infect Public Health* 2022; 15(8): 856-869. <https://doi.org/10.1016/j.jiph.2022.06.013>.
81. Mahdizade M, Mohamadi M, Shadab N, Abbasimoghaddam S, Shekartabar A, Heidary M, Khoshnood S. Neurological manifestations in patients with COVID-19: a systematic review and meta-analysis. *J Clin Lab Anal* 2022; 36(5): 1-13. <https://doi.org/10.1002/jcla.24403>.
82. Houben S, Bonnechère B. The impact of COVID-19 infection on cognitive function and the implication for rehabilitation: a systematic review and meta-analysis. *Int J Environ Res Public Health* 2022; 19(13): 7748. <https://doi.org/10.3390/ijerph19137748>.
83. Domingues R, Leite M, Senne C. Cerebrospinal fluid analysis in patients with COVID-19-associated central nervous system manifestations: a systematic review.

- Arq Neuropsiquiatr 2022; 80(3): 296–305. <https://doi.org/10.1590/0004-282x-amp-2021-0117>.
84. Araújo S, Araújo C, Silva R, Oliveira L, Souza N, Miranda D, Simoes A. Imaging markers of neurologic damage in COVID-19: a systematic review. *Curr Med Chem* 2022; 29. <https://doi.org/10.2174/0929867329666220701124945>.
85. Vizcaino G. Síndrome trombocitopénico inmune trombótico posvacunación. ¿Causalidad o casualidad? Especial referencia a las vacunas Astra-Zeneca COVID-19 (Vaxzevria®). *Gaceta Médica De Caracas*, 2021; 129(3), 665–675. Recuperado a partir de [http://saber.ucv.ve/ojs/index.php/rev\\_gmc/article/view/22888](http://saber.ucv.ve/ojs/index.php/rev_gmc/article/view/22888).
86. Esparza J, Vizcaino G, Pujol FH. Trombosis asociada a vacunas contra la COVID-19 basadas en vectores adenovirales: implicaciones para la vacunación en Venezuela. *CientMed* 2021; 2(28):01-07. [doi.org/10.47449/CM.2021.2.7](https://doi.org/10.47449/CM.2021.2.7).
87. Generoso JS, Barichello de Quevedo JL, Cattani M, Lodetti BF, Sousa L, Collo del, A, Diaz, Dal-Pizzol, F. Neurobiology of COVID-19: how can the virus affect the brain? *Braz J Psychiatry* 2021;43(6):650-664. <https://doi:10.1590/1516-4446-2020-1488>.