








Oral rehabilitation using 3D printed crowns for amelogenesis imperfecta: case report

Bruna Cordeiro Amarante¹ , Camila Gallo Cabral² , Catielma Nascimento Santos^{3,4} , Emerson Junio de Moraes Filho² , Ana Carolina Cheron Gentile⁵ , Marcelo Bönecker⁶ , Marcelo Munhóes Romano⁷ .

Abstract: Amelogenesis imperfecta (AI) is a condition that severely affects tooth enamel. In most cases aesthetics and function are compromised while solutions are scarce and have high cost. The purpose of this case report is to describe a rehabilitation case of a 13-year-old male patient diagnosed with amelogenesis imperfecta. A minimally invasive oral rehabilitation was planned using digital workflow for planning, 3D printing of crowns and S-PRG fillers as an aesthetic and functional solution, with lower cost, in the face of the AI case presented. Case report: 13-year-old male with pain, sensitivity, and aesthetics complaints, the patient has been diagnosed with Amelogenesis Imperfecta Hypomaturation-Hypoplastic, Type IV (AIHHT – OMIM: 104510). Treatment was divided into three phases, preventive and sensitivity management, minimally invasive oral rehabilitation – CAD-CAM and orthodontic treatment. It is possible to conclude that digital flow and 3D printing have many benefits for dentistry such as treatment predictability, chairside and lower material waste, cost and working time. It can also be concluded that digital dentistry allows oral rehabilitation following minimal intervention principles and that it was a successful treatment with aesthetic, function and quality of life improvements.

Key words: Mouth Rehabilitation, Digital Technology, Printing, Three-Dimensional, Amelogenesis Imperfecta, S-PRG Fillers.

Rehabilitación oral utilizando coronas impresas en 3D para amelogénesis imperfecta: reporte de caso

Resumen: La amelogénesis imperfecta (AI) es una condición que afecta gravemente el esmalte dental. En la mayoría de los casos, la estética y la función están comprometidas, mientras que las soluciones son escasas y de alto costo. El objetivo de este reporte de caso es describir un caso de rehabilitación de un adolescente masculino de 13 años con AI. Se planificó una rehabilitación oral mínimamente invasiva utilizando flujo digital de trabajo para planificación, impresión 3D de coronas y el uso de S-PRG fillers como solución estética y funcional, con menor costo, frente al caso de AI presentado. Reporte de caso: paciente masculino de 13 años de edad con quejas de dolor, sensibilidad y estética. El paciente fue diagnosticado con Amelogénesis Imperfecta Hipomaturada-Hipoplástica Tipo IV (AIHHT - OMIM: 104510). El tratamiento se dividió en 3 fases: fase preventiva y de manejo de la sensibilidad, rehabilitación oral siguiendo principios mínimamente invasivos - CAD-CAM y finalmente tratamiento ortodóntico. Es posible concluir que el flujo digital y la impresión 3D tienen muchos beneficios para la odontología, como previsibilidad del tratamiento, menor desperdicio de material, costo y tiempo de trabajo. También se puede concluir que la odontología digital permite la rehabilitación oral siguiendo los principios de mínima intervención y que fue un tratamiento exitoso con mejoras en la estética, función y calidad de vida del paciente.

Palabras clave: Rehabilitación Bucal, Tecnología Digital, Impresión, 3D, Amelogénesis Imperfecta, S-PRG Fillers.

¹Department of Orthodontics and Pediatric Dentistry, School of Dentistry, University of São Paulo, Brazil.

²Integrated Clinic, Department of Stomatology, School of Dentistry, University of São Paulo, Brazil.

³Department of Orthodontics and Pediatric Dentistry, School of Dentistry, University of São Paulo, Brazil.

⁴Department of Dentistry, Federal University of Sergipe, Lagarto, Brazil.

⁵Department of Orthodontics and Pediatric Dentistry, School of Dentistry, University of São Paulo, Brazil.

⁶Professor, Department of Orthodontics and Pediatric Dentistry, School of Dentistry, University of São Paulo, Brazil.

⁷Professor, Integrated Clinic, Department of Stomatology, School of Dentistry, University of São Paulo, Brazil.

Reabilitação oral utilizando coroas impressas em 3D para amelogênese imperfeita: relato de caso

Resumo: A amelogênese imperfeita (AI) é uma condição que afeta gravemente o esmalte dentário. Na maioria dos casos, a estética e a função são comprometidas, enquanto as soluções são escassas e têm alto custo. O objetivo deste relato de caso é descrever um caso de reabilitação de um adolescente do sexo masculino de 13 anos com AI. Foi planejada uma reabilitação oral minimamente invasiva utilizando fluxo digital de trabalho para planejamento, impressão 3D de coroas e o uso de S-PRG fillers como solução estética e funcional, com menor custo, diante do caso de AI apresentado. Relato de caso: paciente do sexo masculino com 13 anos de idade e queixa de dor, sensibilidade e estética. O paciente foi diagnosticado com Amelogênese Imperfeita Hipomaturada-Hipoplásica Tipo IV (AIHHT - OMIM: 104510). O tratamento foi dividido em 3 fases: fase preventiva e de manejo da sensibilidade, reabilitação oral seguindo princípios minimamente invasivos - CAD-CAM e por fim tratamento ortodôntico. É possível concluir que o fluxo digital e a impressão 3D têm muitos benefícios para a odontologia, como previsibilidade do tratamento, menor desperdício de material, custo e tempo de trabalho. Também pode-se concluir que a odontologia digital permite a reabilitação oral seguindo os princípios de mínima intervenção e que foi um tratamento bem-sucedido com melhorias na estética, função e qualidade de vida do paciente.

Palavras-chave: Reabilitação Bucal, Tecnologia Digital, Impressão, 3D, Amelogênese Imperfeita, S-PRG Fillers.

Introduction

Amelogenesis imperfecta (AI) describes a heterogeneous group of clinical and genetic conditions that affect tooth enamel and causes damage to function, due to modified dental structure, affects quality of the enamel, adhesion, and aesthetic, causes hypersensitivity, and also loss of vertical dimension and orthodontic deviations¹⁻³.

To improve function and esthetics, new treatment options are emerging and digital flow with 3D printing has been widely used⁴⁻⁶ in the production of crowns and it uses an additive manufacturing method, stereolithography, that doesn't waste material, has lower cost, optimized resolution, accuracy and smooth surface finish⁷⁻¹⁰.

3D-printed composite resin crowns showed high fracture resistance and can be suggested as a viable solution

in conservative dentistry¹¹. New load-increasing microfilled resins for 3D printing of crowns have benefits such as increased mechanical properties which offers time saving, higher precision, accuracy and fitting, lower risk of distortions, manufacturing of complex shapes (as of crowns with no tooth preparation) and almost no waste of material.

Another new technology is the S-PRG Filler which is a combination of 'glass ionomer cement' and 'resin composite'¹². These materials have high fluoride release, excellent adhesion and aesthetics. Digital flow and 3D prints have enabled minimal intervention oral rehabilitation for pediatric dentistry and cases of developmental enamel defects¹³. The objective of this article is to report an oral rehabilitation case of amelogenesis imperfecta using 3D-printed composite resin crowns with minimal intervention principles.

Case report

This case report was conducted in compliance with the Helsinki Declaration and was prepared according to CARE guideline¹⁴. A 13-year-old male presented to the clinic with pain, sensitivity, and aesthetics complaints. The patient's main complaint was difficulty eating and brushing his teeth due to high hypersensitivity, also as he entered adolescence, the patient reported being bullied at school because of the aesthetics of his teeth. Medical history showed no systemic conditions. Dental history showed that the patient has been diagnosed with Amelogenesis Imperfecta (AI) Hypomaturation-Hypoplastic, Type IV (AIHHT – OMIM: 104510) (Figure 1) and has and an anterior dental crossbite (tooth 12).

AI is a genetic condition resulting from a mutation in genes present in the mineralization process of tooth enamel. Because of this genetic characteristic, people with this condition have enamel malformation in both deciduous and permanent teeth. Treatment began at the age of 13, as this was when the patient arrived at the Enamel Defects Clinic at the School of Dentistry of the University of São Paulo. The family reported that they had been looking for treatment for years, but due to their low socio-economic status they had not been able to find treatment solutions that they could afford and in many public treatment centers they were informed that they did not provide the type of treatment needed due to its cost and complexity.

The treatment plan was conducted according to the timeline below (Table 1 and 2), the initial consultation included a clinical examination, intraoral and extraoral

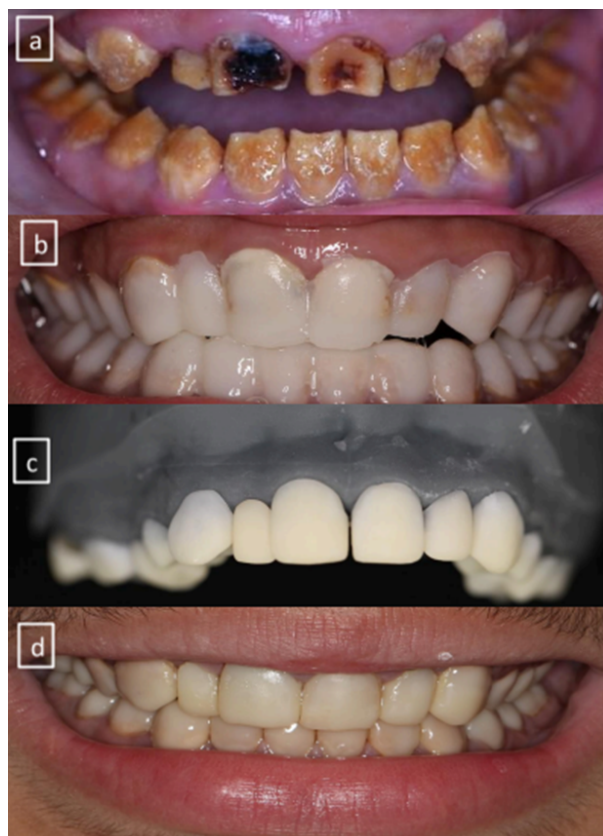

Figure 1. Treatment photos; a) Pre-operative (initial) photo; b) Mockup; c) Printed crowns; d) Post-operative (final) photo.

photographs, and complementary tests such as panoramic radiography and intraoral scans. One week after the initial consultation, phase 1 of the treatment began, which consisted of preparing the oral environment for rehabilitation, with two sessions of supra- and subgingival scraping, with a week in between, for hygiene and dental tartar removal. Next, a sensitivity management protocol was carried out using an infrared laser associated with fluoride varnish (Table 1). Four sessions of the protocol were carried out once a week.

The minimally invasive rehabilitation was performed with the use of an intraoral scanner, digital planning software and

Table 1. Treatment plan and protocols.

Dental examination and case discussion with multidisciplinary team			
Clinical exam	Digital photos	Panoramic radiography	Intraoral scanning
Phase 1 = Preventive and sensitivity management: infrared laser protocol for sensitivity and gingival treatment			
Infrared laser protocol: 1 session per week for 4 weeks (780nm, 70mW, 105J/cm ² – 60 seconds per tooth)	Fluoride varnish protocol: application once a week for 4 weeks	Oral hygiene and diet guidelines were presented	2 sessions of gingival treatment
Phase 2 = Minimally invasive oral rehabilitation – CAD-CAM			
1. Rehabilitation planning	2. Digital planning of functional characteristics	3. Aesthetic planning	4. Printed waxed-up models and bis-acryl mock-up
5. Resin preparation: vibration at a speed of 85rpm for 20 minutes	6. Printer parameters for resin - NextDent C&B MFH (Table 3)	7. Positioning of crowns in the printing plate	8. Crown printing: 1 hour and 30 minutes
9. Post-printing process: ultrasound wash	10. Post-curing process: (Light source: UV LED; wavelength: 405nm, light output: 40W (two 10W side lamps and one 20W top lamp); heating frequency: 70W; rotation speed: 15 turns/minute	11. Crown polishing	12. Crown cementation with no wear of dental structure
Phase 3 = Orthodontic treatment			

3D printing (Table 2, Figures 2 and 3). The planning software was used to plan all functional characteristics such as thickness and orientation of the printed layer, printing orientation and position, build angle, vertical dimension, crown sizes and occlusal dimension. The patient's waxed-up models were printed, and a bis-acryl mock-up was made to try on the characteristics planned on the software (Figures 1 and 2).

The printing process and parameters are explained in Tables 1 and 3, after printing the crowns were placed in ultrasound (Table 2) with 99,5% alcohol for 5 minutes and then post-curing process (Table 1) in the curing oven (Table 2 and Figure 3) for 10 minutes, polishing and final glaze. Crowns installations were performed one tooth at

a time. ResiCem Universal Resin Cement (Table 2) has the highest reported bond strengths of any resin cement, has excellent adhesion and aesthetics, customized to be universal for all materials, high fluoride release and very low film thickness (9µm)¹⁵.

Operatory phase and crown placement followed the steps: 1) Prophylaxis; 2) Try in crowns; 3) Selective surface etching – ortho-phosphoric acid 37% ; 4) Wash and dry; 5) 2 step adhesives (Table 2); 6) Cement injection and crown placement; 7) Photoactivation 20 seconds (Table 2); 8) Flossing and cleaning all excesses (diamond burs and abrasive discs/stripes); 9) Occlusal adjustment (carbon paper and finishing burs); 10) Photographs were taken during the whole process (Figure 4). The printed crowns were cemented

Table 2. List of materials and devices.

Device/Material	Model and Brand
Vibration device for resin preparation	Orbit P4, Labnet International Inc., USA
Printing software	FlashDLPrint 2.2.1, 64 Bits (Zhejiang Flashforge 3D Technology Co, China)
Ultrasound	YX-2050, Super Power technologies, Paraguay
Resin cement	Shofu's ResiCem Universal Resin Cement (SHOFU INC. – Kyoto Japan).
Adhesives	ResiCem Primer A (Crown surface) and B (Tooth surface) - SHO-FU INC
LED curing light	VALO Cordless – Ultradent
Intraoral scanner	Straumann Virtuo Vivo, Straumann, Switzerland
Digital planning software	EXOCAD, Exocad GmbH, Germany
Printer	FlashForge Hunter, Zhejiang Flashforge 3D Technology Co, China
Curing oven	Done3D
Resin for crown manufacture	NextDent/Vertex- Dental B.V.–NextDent Netherlands

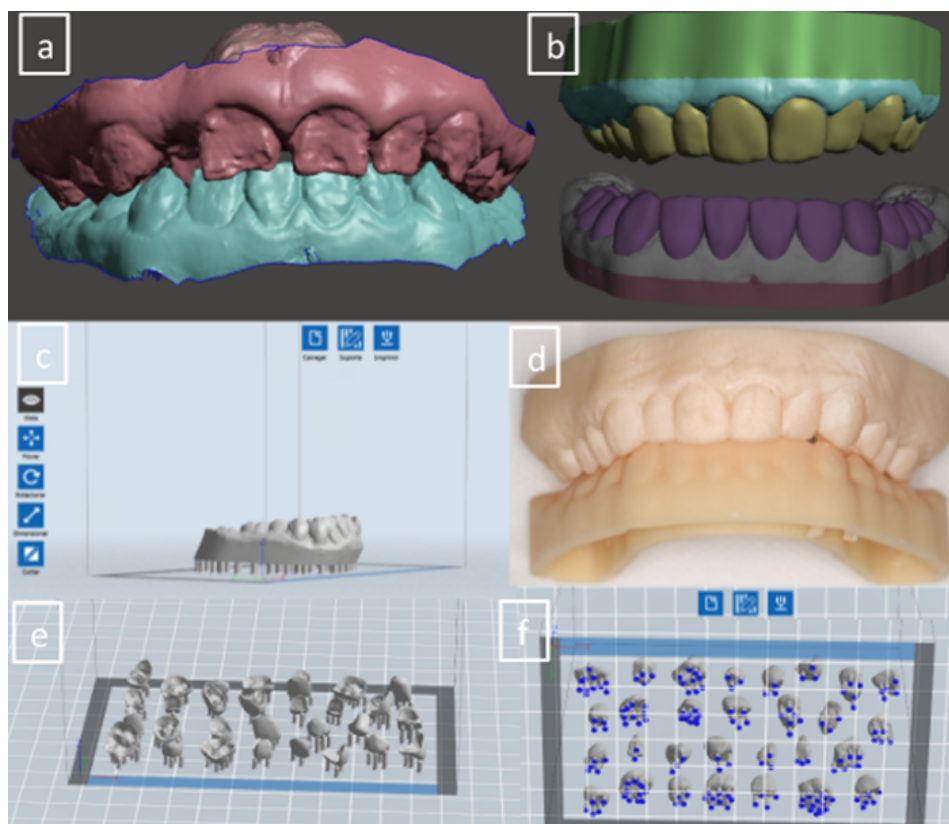


Figure 2. Digital planning: a) Initial intraoral scanning; b) Waxed up models - planning software EXOCAD for crown design; c) Model printing plan; d) 3D printed waxed up model; e) Crown planning on printing software; f) Support positions for crown printing.




Figure 3. 3D printing process: a) Vibration for resin preparation; b) 3D printer; c) Ultrasound wash; d) Curing oven; e) Printed crowns (lateral vision of supports); f) Printed crowns on printer bed.

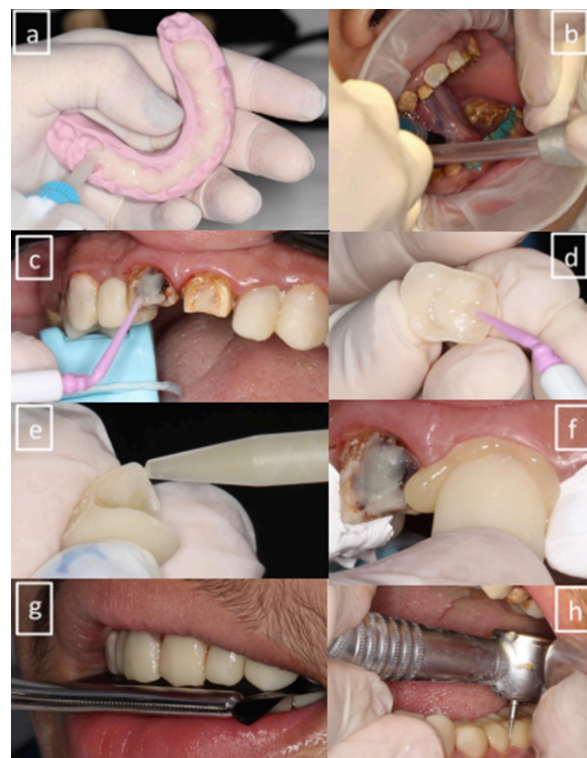


Figure 4. Summary of operative steps for oral rehabilitation: a) Mockup; b) Surface etching; c) Tooth surface adhesive; d) Crown surface adhesive; e) Cement injection; f) Crown placement; g) Occlusal adjustment; h) Polishing with finishing burs.

directly onto the tooth structure without any tooth preparation.

The whole treatment process took approximately 3 months and 10 dental appointments with one week interval

between the first 6 appointments (Phase 1) and two-week intervals between the next 4 appointments (Phase 2). In phase 1, we opted for weekly appointments so that the sensitivity protocol would be more successful. In the second phase,

Table 3. Printer parameters for NextDent C&B MFH resin.

Resin	Layer Thickness	Curing time for each layer	Adhesion layers	Curing time for adhesion layers	Light intensity
NextDent C&B MFH	0,05mm	2,5 seconds	8 layers	15 seconds	90%

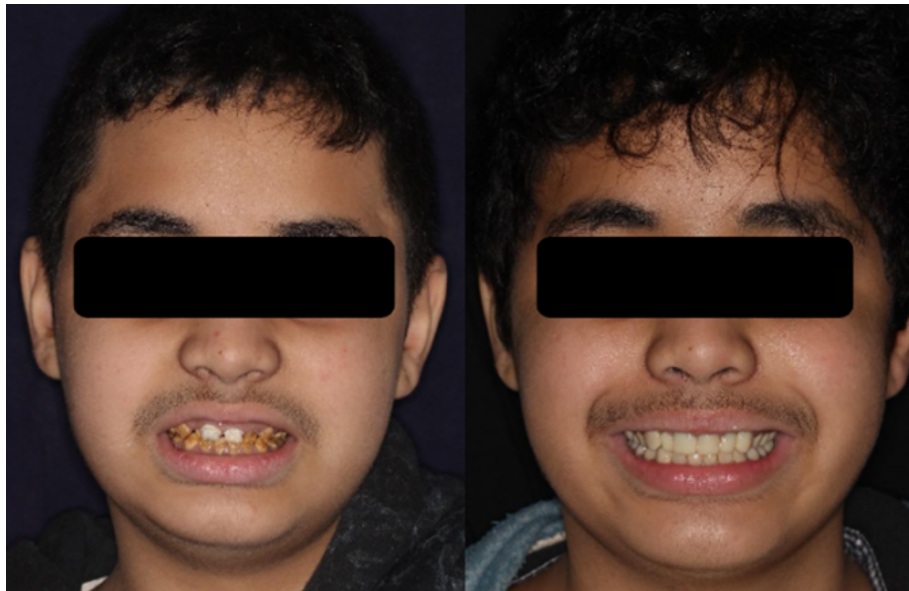

Figure 5. Before and after treatment.

appointments were made every 15 days, due to the need to plan and produce the crowns and also so that the patient would have a longer period to adapt to the new crowns, as there were major aesthetic changes and also in relation to the occlusal vertical dimension.

This rehabilitation process allowed the continuity of the patient's treatment, with the adhesion of orthodontic fixed appliance parts. Follow-up appointments were conducted weekly during the first month after crown installation. In the subsequent two months, appointments were held every 15 days, and after this initial period, the patient attended monthly appointments for monitoring. After 1 year of follow up it was possible to install fixed orthodontic appliances and there was no damage to crowns and adhesion in this period, the crowns were stable in the oral cavity (Figure 5).

Discussion

This case report describes the use of new technology combined with well-defined dentistry principles like the use of minimally invasive treatments for pediatric dentistry. The main complaints of the patient were hypersensitivity, aesthetics and function, also the high rehabilitation cost. The traditional methods for oral rehabilitation in pediatric dentistry for amelogenesis imperfecta in permanent teeth are composite restorations, composite, ceramic, and zirconia crowns, which present great aesthetic improvement but all of those need tooth preparation, wear of dental surface and has higher cost^{4,5}. As far as we are aware, there are no other case reports that have used 3D-printed crowns for the oral rehabilitation of patients with amelogenesis imperfecta following the principles of minimal intervention. Most cases reported have undertaken conventional rehabilitative procedures,

including dental preparation and the use of laboratory-fabricated crowns^{4,5}.

When the patient arrived for treatment, we realized it was a complex oral rehabilitation case, and the family could not afford the costs of conventional rehabilitation (crowns produced by dental laboratories). Therefore, we had to consider a treatment option that was affordable, did not rely on third-party work (laboratories), and could be performed using the materials and equipment available at the university clinic.

3D printing is already well used in prosthetic rehabilitation, it has successfully established function and aesthetics and it can also be used, as shown in this article, as a minimally invasive technique¹³, because digital planning allows the cementation of crowns/veneers without wear of dental tissue and has an accessible cost.

Regarding the cost of resin-printed crowns, after the initial investment in a 3D printer, resin, curing oven, and ultrasonic washer, the approximate cost of a printed crown is \$2.00 (R\$10.00 - Brazilian currency). When compared to metal-free crowns produced in a laboratory, despite the initial investment in the necessary equipment, since it is third-party work, it is not possible to pay the cost price. Therefore, the final price of a metal-free crown made by a laboratory is approximately \$70.00 (R\$400) in Brazil, which is significantly higher.

A major difficulty in AI cases is adhesion. Success rates for adhesively bonded single-

tooth restorations in AI patients compared with patients without AI presented by Klink, Groten & Huettig (2018)³ were high, giving us encouragement regarding the case report presented and the long-term durability of cement-retained crowns. Shofu's resin cement was a success, with no adhesion failures after one year of follow up.

Conclusion

It is possible to conclude that digital workflow and 3D printing have many benefits for dentistry such as treatment predictability, lower cost, less material waste, shorter working time, independence in the production of prosthetic parts and better communication with the patient, this case shows that digital dentistry made possible to perform oral rehabilitation following minimally invasive principles and reestablishing not only function but also aesthetic⁷⁻¹⁰.

We concluded that the case was a success, greatly improving the patient's aesthetics and function, with an improvement in quality of life, diet and hygiene due to the improvement in sensitivity.

Conflict of Interest

The authors declare that they have no conflict of interest regarding the publication of this article.

References

1. Aldred MJ, Savarirayan R, Crawford PJ. Amelogenesis imperfecta: a classification and catalogue for the 21st century. *Oral Dis.* 2003 Jan;9(1):19-23. doi: 10.1034/j.1601-0825.2003.00843.x. PMID: 12617253.

2. Smith CEL, Poulter JA, Antanaviciute A, Kirkham J, Brookes SJ, Inglehearn CF, Mighell AJ. Amelogenesis Imperfecta; Genes, Proteins, and Pathways. *Front Physiol.* 2017 Jun 26;8:435. doi: 10.3389/fphys.2017.00435. PMID: 28694781; PMCID: PMC5483479.
3. Klink A, Groten M, Huettig F. Complete rehabilitation of compromised full dentitions with adhesively bonded all-ceramic single-tooth restorations: Long-term outcome in patients with and without amelogenesis imperfecta. *J Dent.* 2018 Mar;70:51-58. doi: 10.1016/j.jdent.2017.12.011. Epub 2017 Dec 21. PMID: 29275170.
4. Toupenay S, Fournier BP, Manière MC, Ifi-Naulin C, Berdal A, de La Dure-Molla M. Amelogenesis imperfecta: therapeutic strategy from primary to permanent dentition across case reports. *BMC Oral Health.* 2018 Jun 15;18(1):108. doi: 10.1186/s12903-018-0554-y. PMID: 29907114; PMCID: PMC6003150.
5. Roma M, Hegde P, Durga Nandhini M, Hegde S. Management guidelines for amelogenesis imperfecta: a case report and review of the literature. *J Med Case Rep.* 2021 Feb 9;15(1):67. doi: 10.1186/s13256-020-02586-4. PMID: 33557885; PMCID: PMC7871387.
6. P.H. Corazza, H.L. de Castro, S.A. Feitosa, E.T. Kimpara, A. Della Bona. Influence of CAD-CAM diamond bur deterioration on surface roughness and maximum failure load of Y-TZP-based restorations. *Am J Dent.* 28 (2015), pp. 95-99
7. Della Bona A, Cantelli V, Britto VT, Collares KF, Stansbury JW. 3D printing restorative materials using a stereolithographic technique: a systematic review. *Dent Mater.* 2021 Feb;37(2):336-350. doi: 10.1016/j.dental.2020.11.030. Epub 2021 Jan 19. PMID: 33353734; PMCID: PMC7855936.
8. van Noort R. The future of dental devices is digital. *Dent Mater.* 2012 Jan;28(1):3-12. doi: 10.1016/j.dental.2011.10.014. Epub 2011 Nov 26. PMID: 22119539.
9. Stansbury JW, Idacavage MJ. 3D printing with polymers: Challenges among expanding options and opportunities. *Dent Mater.* 2016 Jan;32(1):54-64. doi: 10.1016/j.dental.2015.09.018. Epub 2015 Oct 20. PMID: 26494268.
10. Melchels FP, Feijen J, Grijpma DW. A review on stereolithography and its applications in biomedical engineering. *Biomaterials.* 2010 Aug;31(24):6121-30. doi: 10.1016/j.biomaterials.2010.04.050. Epub 2010 May 15. PMID: 20478613.
11. Corbani K, Hardan L, Skienhe H, Özcan M, Alharbi N, Salameh Z. Effect of material thickness on the fracture resistance and failure pattern of 3D-printed composite crowns. *Int J Comput Dent.* 2020;23(3):225-233. PMID: 32789310.
12. Francois P, Fouquet V, Attal JP, Dursun E. Commercially Available Fluoride-Releasing Restorative Materials: A Review and a Proposal for Classification. *Materials (Basel).* 2020 May 18;13(10):2313. doi: 10.3390/ma13102313. PMID: 32443424; PMCID: PMC7287768.
13. Joo HS, Park SW, Yun KD, Lim HP. Complete-mouth rehabilitation using a 3D printing technique and the CAD/CAM double scanning method: A clinical report. *J Prosthet Dent.* 2016 Jul;116(1):3-7. doi: 10.1016/j.prosdent.2016.01.007. Epub 2016 Mar 2. PMID: 26946918.
14. Gagnier JJ, Kienle G, Altman DG, Moher D, Sox H, Riley D, et al. The CARE guidelines: consensus-based clinical case report guideline development. *J Clin Epidemiol.* 2014;67(1):46-51.
15. SHOFU INC. Website - <https://www.shofu.com/en/product/resicem-universal-resin-cement/> - 2022

Recibido 16/02/24

Aceptado 15/06/24

Correspondencia: Bruna Cordeiro Amarante: bruna.amarante@usp.br; bruamarante95@gmail.com